

American Journal of Psychology and Brain Studies

<https://urfpublishers.com/journal/american-psychology>

Vol: 1 & Iss: 1

Ropy and Threadlike-Desmoid Fibromatosis

Anubha Bajaj*

A.B. Diagnostics, New Delhi, India

Citation: Bajaj, A. (2023) Ropy and Threadlike-Desmoid Fibromatosis. *Am J Psychol & Brain Stud*, 2023;1(1):1-3.

Received: 11 May, 2023; **Accepted:** 25 May, 2023; **Published:** 30 May, 2023

***Corresponding author:** Anubha Bajaj, A.B. Diagnostics, New Delhi, India. Tel: +919811693956, E-mail: anubha.bajaj@gmail.com

Copyright: © 2023 Bajaj, A. This is an open-access article published in *Am J Psychol & Brain Stud* and distributed under the terms of the Creative Commons Attribution License, which permits unrestricted use, distribution, and reproduction in any medium, provided the original author and source are credited.

Introduction

Desmoid fibromatosis emerges as a benign neoplasm of fibroblastic or myofibroblastic origin associated with infiltrative tumour perimeter, localized tumour aggression, predilection for tumour recurrence and an absent potential for distant metastasis. Desmoid fibromatosis may be associated with familial adenomatous polyposis or Gardner syndrome. Additionally designated as aggressive fibromatosis, musculoaponeurotic fibromatosis, desmoid tumour or deep fibromatosis, neoplasm commonly emerges within deep seated soft tissues.

Morphologically, desmoid fibromatosis is minimally to moderately cellular and exhibits elongated, sweeping fascicles of tumour cells intermingled with thin walled vascular articulations and foci of micro-haemorrhages. Neoplastic cells are uniform and exhibit minimal cellular or nuclear atypia. Tumour cells appear immune reactive to smooth muscle actin (SMA) and nuclear β catenin. Besides genomic mutations within CTNNB1 and APC genes may ensue.

Desmoid fibromatosis configures < 3% of soft tissue neoplasms. Around 10% to 30% individuals with familial adenomatous polyposis exemplify desmoid fibromatosis, thereby configuring Gardner syndrome. In contrast, up to 16% of subjects with fibromatosis enunciate familial adenomatous polyposis.

Mean age of disease emergence is 36 years to 42 years. Desmoid fibromatosis exhibits a female preponderance within incriminated pubertal subjects or individuals up to 40 years whereas an equivalent gender predilection is encountered within pre-pubertal and older population with male to female ratio as 1:1 [1,2].

Desmoid fibromatosis concurrent with familial adenomatous polyposis exhibits a male predominance with male to female proportion of ~3:1. Around 50% neoplasms emerge within

the abdominal region. Besides, tumefaction is commonly encountered within extra-abdominal sites as shoulder girdle, chest wall and inguinal region [1, 2].

Desmoid fibromatosis associated with familial adenomatous polyposis is predominantly intra-abdominal or confined to abdominal wall. In contrast, sporadic lesions commonly configure as extra-abdominal neoplasms. Premenopausal or pregnant females may develop fibromatosis within musculoaponeurosis of abdominal wall [1,2].

Majority (~90%) of neoplasms depict CTNNB1 and APC genetic mutations. Neoplastic emergence may be driven by combination of genetic mutations, elevated serum oestrogen levels and antecedent trauma, factors which induce activation of canonical Wnt / β catenin pathway. Majority (~90%) of desmoid fibromatosis exhibit genomic mutations confined to exon 3 of CTNNB1 gene. Commonly, genetic mutations emerge within T41A, S45F or S45P genes. Individuals with familial adenomatous polyposis (FAP) display germline mutations within APC gene with consequent deregulation of Wnt / β catenin pathway [2,3].

Extra-abdominal neoplasms appear as deep seated, inadequately circumscribed, painless lesions. Characteristically, neoplasms confined to abdominal wall incriminate gravid or postpartum females. Intra-abdominal tumours occur as gradually progressive, painless tumefaction which may simulate ovarian neoplasms [2,3].

Upon cytological examination, tumefaction is comprised of bland, spindle shaped cells pervaded with elongated, fusiform nuclei and metachromatic matrix substance. Tumour cells may emerge as individual, singular cells or configure cellular fragments embedded within the matrix. Spindle shaped tumour cells may exemplify an elongated, fascicular arrangement. Neoplasm can be appropriately discerned upon fine needle

aspiration although tissue sampling with core needle biopsy is preferred and recommended [2,3].

Upon gross examination, a characteristic, inadequately defined or well circumscribed tumefaction of magnitude 5 centimetres to 10 centimetres is encountered. Cut surface appears as firm, glistening, whitish, gritty and traversed with coarse trabeculae reminiscent of scar tissue [2,3]. Upon microscopy, neoplasm characteristically enunciates an inadequately defined perimeter. Desmoid fibromatosis expounds microscopic variants denominated as the commonly discerned, conventional neoplastic configuration may configure comprehensive, focal areas. Tumefaction is composed of elongated, sweeping cellular fascicles constituted of elongated, slender, uniform, spindle shaped cells incorporated with pale cytoplasm. Hyperchromatic nuclei are absent. Cytological atypia and mitotic activity is minimal with focally enhanced mitotic figures. Tumour cells are circumscribed by a collagenous stroma. Thin walled, prominent vascular articulations, perivascular oedema or vascular micro-haemorrhages may be encountered. the hypo-cellular, hyalinised tumour pattern is frequent and exhibits prominent stromal hyalinization with compressed, thin walled vascular articulations[3,4]. the staghorn vessel pattern is observed in 20% instances and is composed of prominent, distended, branching vascular articulations. The Myxoid pattern emerges in 15% tumours and demonstrates a preponderant myxoid stroma with minimal, discrete, cellular fascicles.

Neoplasm is devoid of characteristic, thin walled, vascular articulations. The keloidal pattern ensues in ~15% neoplasms which are comprehensively configured of bands of keloidal collagen fibres of variable magnitude. Fascicles of tumour cells are disrupted and characteristic vascular articulations appear absent. the nodular fasciitis-like pattern appears in ~10% instances and is constituted of spindle shaped to stellate cells embedded within a loose, tissue-culture like cellular stroma. Varying quantities of stromal haemorrhage may ensue [3,4]. The hyper-cellular pattern is discerned in 5% subjects and simulates conventional tumour pattern. However, enhanced cellular density and frequently overlapping cellular nuclei may be encountered. Foci of cytological atypia or hyperchromatic nuclei are absent. Upon ultrastructural examination, tumour cells depict features of fibroblastic and Myofibroblastic differentiation as intra-reticular collagen fibres, attenuated filament bundles and Cytoplasmic dense bodies [3,4].

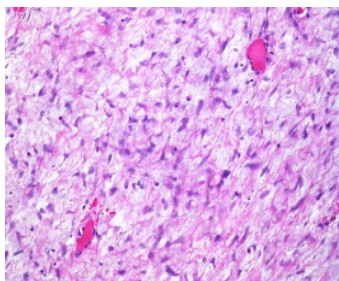


Figure 1: Desmoid fibromatosis depicting elongated fascicles of uniform spindle shaped cells imbued with pale cytoplasm and slender, elongated nuclei. Hyperchromatic nuclei are absent. Surrounding stroma is collagenous and pervaded with prominent, thin walled vascular articulations [6].

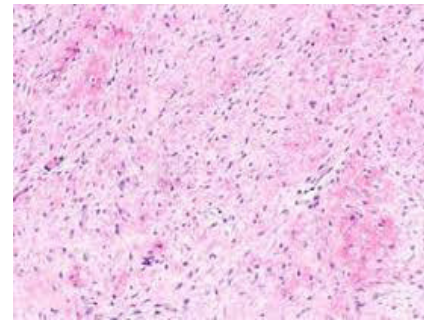


Figure 2: Desmoid fibromatosis delineating bundles of uniform spindle shaped cells permeated with pale cytoplasm and slender, elongated nuclei. Circumscribing stroma is collagenous and pervaded with thin walled vascular configurations [7].

Desmoid fibromatosis appears immune reactive to smooth muscle actin (SMA), muscle specific actin(MSA), desmin, β catenin, cyclin D1, calretinin, oestrogen receptor, progesterone receptor, androgen receptor, vimentin or cathepsin D. Desmoid fibromatosis appears immune non-reactive to CD34, S100 protein, cytokeratin, DOG1, c-kit, ALK1, STAT6 or MUC4.

Ki67 proliferation index is minimal and varies from 1% to 3% [4,5].

Desmoid fibromatosis requires segregation from neoplasms such as dermatological manifestations of Gardner fibroma, scar tissue, palmar or plantar fibromatosis, nodular fasciitis, proliferative fasciitis, proliferative myositis, myofibroma or myofibromatosis, calcifying fibrous pseudo-tumour, sclerosing mesenteritis or idiopathic retroperitoneal fibrosis, solitary fibrous tumour, gastrointestinal stromal tumour (GIST), leiomyoma, nerve sheath tumours, fibrosarcoma, inflammatory myofibroblastic tumour, low grade myofibroblastic sarcoma, low grade fibromyxoid sarcoma, carcinoma breast or familial colonic polyposis [4,5].

Upon ultrasonography, a palpable mass confined to sites such as extremities, abdominal wall, thoracic wall or breast may be encountered. Tumefaction appears as a solid, elliptical, well defined to inadequately defined soft tissue mass of variable echogenicity. Tumour may demonstrate attenuated, linear extension along various fascial planes, thereby configuring 'fascial tail sign' or intramuscular, finger-like tumour expansion with occurrence of 'staghorn sign' [4,5]. Computerized tomography (CT) is commonly adopted for categorizing intra-abdominal tumours and associated complications as obstruction of small bowel. Upon computerized tomography, a soft tissue tumefaction with well-defined to inadequately defined margin, variable attenuation and mild to moderate image enhancement is encountered [4,5]. Magnetic Resonance Imaging (MRI) is a preferred investigative modality for detecting neoplasms confined to abdominal wall or extra-abdominal sites. Upon T1 weighted imaging, tumefaction with signal intensity isointense to surrounding skeletal muscle is encountered. Upon T2 weighted imaging, tumefaction appears as heterogeneous and isointense to hyper-intense to circumscribing skeletal muscle. Majority (90%) of neoplasms delineate non enhancing linear bands, thus configuring a 'band sign'. Magnetic resonance imaging with gadolinium contrast exhibits moderate to significant image enhancement [4,5].

Desmoid fibromatosis exhibits a variable biological course with up to 25% neoplasms exhibiting spontaneous retrogression. Neoplasm may be managed conservatively with extended clinical monitoring and simple observation. Surgical extermination of the neoplasm is associated with significant tumour related morbidity.

Singular radiotherapy or surgical intervention with adjuvant radiotherapy ameliorates localized tumour control, in contrast to adoption of singular surgical intervention. However, employment of extended radiation therapy requires circumvention, especially within incriminated young subjects [4,5].

Advanced disease can be appropriately managed with systemic therapy comprised of first line anti-hormonal agents as tamoxifen which appears beneficial within asymptomatic subjects. Alternatively, nonsteroidal anti-inflammatory drugs (NSAIDs) or conventional chemotherapy as doxorubicin and dacarbazine combination or pegylated liposomal doxorubicin may be advantageously employed. Adoption of response evaluation criteria in solid tumours (RECIST) trial delineates certain response to receptor tyrosine kinase inhibitors wherein sorafenib and sunitinib appear efficacious as compared to imatinib [4,5].

An estimated ~30% desmoid fibromatosis demonstrate localized tumour reoccurrence. Adequacy of surgical perimeter can optimally predict emergence of localized tumour reoccurrence within primary tumours although remains an insignificant contributory factor for assessing repetitive neoplasms. [4,5].

Clinical manifestations as age of disease occurrence, gender predilection, tumour magnitude, tumour site and pertinent histological subtypes emerge as inconsistent factors predicting prognostic outcomes, tumour reappearance or distant metastasis. Comprehensive surgical excision of neoplasm confined to specific locations may engender significant morbidity and tumour associated mortality. Genetic mutation CTNNB1::S45F is associated with proportionate enhancement of tumour reoccurrence [4,5].

References

1. Prendergast K, Kryeziu S, Crago A. (2022).The Evolving Management of Desmoid Fibromatosis. *Surg Clin North Am.*102:4:667-677
2. Riedel RF, Agulnik M (2022).Evolving strategies for management of desmoid tumor.*Cancer* 128:16:3027-3040.
3. Geisenhainer K, Klenke D, Moser N Et al, (2022).Desmoid fibromatosis in the pharyngeal wall: A case report and literature review. *Clin Case Rep.*10:1:e05268.
4. Master SR, Mangla A, Puckett Y Et al. (2022).Desmoid Tumor. *Stat Pearls International*, Treasure Island, Florida.
5. Ormonde M, Argyropoulou D, Lourenço C Et al (2022).Pelvic Desmoid Tumor: A Rare Case with Difficult Diagnosis and Treatment. *Case Rep Obstet Gynecol.* 2022:7653246.