

Refitted and Contemporary-Nottingham Grading-Carcinoma Breast

Anubha Bajaj*

Consultant Histopathologist, Department of Histopathology, A.B. Diagnostics, Delhi, India

*Corresponding author: Dr. Anubha Bajaj, Department of Histopathology, AB Diagnostics, A-1, Ring Road, Rajouri Garden, New Delhi- 110027, India, Tel: +91 9811693956, Email: anubha.bajaj@gmail.com; anubha.bajaj@yahoo.com

Citation: Bajaj, A. (2023). Refitted and Contemporary-Nottingham Grading-Carcinoma Breast. *J Adv Biomed Eng*, 1(1), 1-2.

Received: 17 December, 2022; Accepted: 04 January, 2023; Published: 09 January, 2023

Copyright: © 2023 Bajaj A. This is an open-access article distributed under the terms of the Creative Commons Attribution License, which permits unrestricted use, distribution, and reproduction in any medium, provided the original author and source are credited.

Introduction

Characteristically, factors such as tumour burden confined to mammary parenchyma, extent of metastatic disease within ipsilateral regional lymph nodes and tumour grade contribute as pathognomonic histopathological parameters for ascertaining prognostic outcomes of carcinoma breast, especially in antecedent lesions accompanied with locally advanced disease. Aforesaid contributory factors appear to be validated for histopathological and molecular categorization of carcinoma breast.

Elston/Nottingham modification of **Bloom-Richardson** system is a commonly employed, contemporary classification criterion of evaluating carcinoma breast.

Nottingham Bloom-Richardson grading system is contingent to morphological features as

~configuration of tubules by the tumour.

~quantifiable mitotic figures per 10 high power fields as exemplified within actively proliferating, cellular areas.

~occurrence of nuclear pleomorphism.

The neoplasm is efficaciously graded subsequent to appropriate assessment of representative segment of the neoplasm, in contrast to assessing minimally differentiated portion (1,2).

Configuration of tumour tubules contributes to pertinent scoring and is classified as

~ 1 point: tubules representing > 75% of tumefaction.

~2 points: tubules articulating 10% to 75% of tumefaction.

~3 points: tubules manifesting < 10% of tumefaction.

Comprehensive countenance of the neoplasm mandates appropriate consideration while scoring configuration of tubules. Articulated tubules necessitate clear centric lumens for cogent categorization and quantification (1,2).

Mitotic figures are appropriately evaluated upon tumour

periphery and are aptly quantified within mitotically active areas. Estimation of mitotic figures confined within 10 high power fields (hpf) constituting a singular, non contiguous neoplastic area is optimal. Representative fields with maximal tumour zone are selected whereas poorly preserved areas require circumvention. Cellular component with hyperchromatic and pyknotic nuclei demonstrating apoptosis mandate exclusion from evaluation of quantifiable mitotic activity (1,2).

Nuclear pleomorphism is classified as

~1 point: neoplasms depicting minimal variation of nuclear magnitude and outline with configuration of miniature, regular, uniform neoplastic cells.

~2 points: neoplasms delineating moderate variation in nuclear magnitude and outline.

~3 points: neoplasms demonstrating significant variation in nuclear magnitude and outline.

Tumour zones exemplifying maximal cellular and nuclear atypia are optimal for assessment of nuclear pleomorphism (2,3).

Precise evaluation of infiltrating lobular carcinoma is preferentially achieved by employing a two tiered grading system of assessing nuclear pleomorphism.

Thus classified, carcinoma breast is **graded** and **scored** as

~3 - 5 points: accumulated by well differentiated, grade I carcinoma breast.

~6 - 7 points: accumulated by moderately differentiated, grade II carcinoma breast.

~8 - 9 points: accumulated by poorly differentiated, grade III carcinoma breast (2,3).

Clinical or pathological staging of carcinoma breast as per American Joint Committee of Cancer (AJCC) is contingent to factors such as

~ extent and magnitude of tumour.



Figure 1: Graphic description of Nottingham grading of invasive carcinoma breast (5).

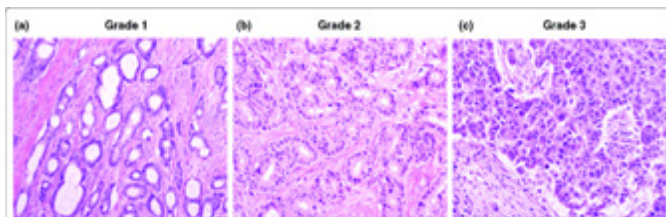


Figure 1: Tubule formation, mitotic activity and nuclear pleomorphism as assessed with Nottingham score for grading invasive carcinoma breast (6).

Table 1: Quantifiable mitotic figures in proliferating zones/10hpf (2,3).

Score	(a)	(b)	(c)
1 point	0-5	0-9	0-11
2 points	6-11	10-19	12-22
3 points	11+	20+	23+

- ~(a) field diameter of 0.44 millimetres
- ~(b) field diameter of 0.59 millimetres
- ~(c) field diameter of 0.63 millimetres

Table 2: Pathologic staging of invasive carcinoma breast (NOS) (3,4).

Stage	T score	N score	M score
0	Tis	N0	M0
Stage I			
IA	T1	N0	M0
IB	T0	N1(mi+)	M0
IB	T1	N1(mi+)	M0
Stage II			
IIA	T0	N1	M0
IIA	T1	N1	M0
IIA	T2	N0	M0
IIB	T2	N1	M0
IIB	T3	N0	M0
Stage III			
IIIA	T0	N2	M0
IIIA	T1	N2	M0
IIIA	T2	N2	M0
IIIA	T3	N1 or N2	M0
IIIB	T4	N0, N1 or N2	M0
IIIC	Any T score	N3	M0
Stage IV			
IV	Any T score	Any N score	M1

- ~tumour metastasis into regional lymph nodes with quantification.
- ~tumour metastasis into distant viscera as pulmonary or hepatic parenchyma.
- ~status of oestrogen receptors (ER).
- ~status of progesterone receptors.
- ~status of HER2/neu receptors.
- ~grading of carcinoma as well differentiated, poorly differentiated or with intermediate differentiation.
- ~oncotype DX recurrence score applicable to preliminary stage lesions of carcinoma breast (2,3). Precise histological tumour grade is a significant predictor of tumour associated survival. Invasive disease-free survival (DFS) is denominated as ‘absence of invasive disease, tumour recurrence or tumour associated mortality’.

Overall survival (OS) is denominated as ‘mortality due to various contributory factors’. Tumour recurrence is designated as ‘relapse of primary carcinoma breast following treatment with curative intent’.

However, it is posited that **Nottingham Bloom-Richardson grading** system demonstrates minimal reproducibility wherein moderately differentiated neoplasms may be challenging to ascertain (3,4).

Neoplasms delineating a 3 + 3 + 1 tumour configuration articulating < 10% neoplastic tubules, significant nuclear pleomorphism with minimal mitotic figures may demonstrate minimal mitotic count on account of contributory factors such as unsatisfactory tumour fixation directly following surgical eradication. Consequently, tumour cells may accomplish cellular division with subsequently decimated observation of mitotic figures. Alternatively, Ki67 proliferation index may be employed as a surrogate indicator of neoplastic proliferation and assessing quantifiable mitotic figures, especially within aforesaid instances (3,4).

References

1. Zhou L, Rueda M, Alkhateeb A. Classification of Breast Cancer Nottingham Prognostic Index Using High-Dimensional Embedding and Residual Neural Network. *Cancers (Basel)*. 2022; 14(4):934. PMID: 35205681, PMCID: [PMC8870306](https://pubmed.ncbi.nlm.nih.gov/38870306/), DOI: [10.3390/cancers14040934](https://doi.org/10.3390/cancers14040934)
2. Kerin EP, Davey MG, McLaughlin RP et al. Comparison of the Nottingham Prognostic Index and OncotypeDX® recurrence score in predicting outcome in estrogen receptor positive breast cancer. *Breast*. 2022; 66:227-235. PMID: [36335747](https://pubmed.ncbi.nlm.nih.gov/36335747/), DOI: [10.1016/j.breast.2022.11.001](https://doi.org/10.1016/j.breast.2022.11.001)
3. Takahashi H, Oshi M, Asaoka M et al. Molecular Biological Features of Nottingham Histological Grade 3 Breast Cancers. *Ann Surg Oncol*. 2020; 27(11):4475-4485. PMID: 32436191, PMCID: [PMC7808708](https://pubmed.ncbi.nlm.nih.gov/7808708/), DOI: [10.1245/s10434-020-08608-1](https://doi.org/10.1245/s10434-020-08608-1)
4. van Dooijeweert C, van Diest PJ, Ellis IO. Grading of invasive breast carcinoma: the way forward. *Virchows Arch*. 2022 ;480(1):33-43. PMID: 34196797, PMCID: [PMC8983621](https://pubmed.ncbi.nlm.nih.gov/38983621/), DOI: [10.1007/s00428-021-03141-2](https://doi.org/10.1007/s00428-021-03141-2)
5. Image 1 Courtesy: *John Hopkins University*.
6. Image 2 Courtesy: *Research gate*.