

American Journal of Psychology and Brain Studies

<https://urfpublishers.com/journal/american-psychology>

Vol: 1 & Iss: 1

Mixed Tremor in Parkinsonian Syndromes: A Study of Clinical Evolution and Treatment in Patients of Local Outpatients Parkinsons Disease and Movement Disorder Unit

Flora Zarola^{1*}, Rita Bartolomei², Nicola S Tiberio³, Pier Luigi Vassallo⁴

¹M.D., PhD., Unit of Parkinson's Disease and Movement Disorders 2 ASL RM 6

²M.D, Coordinator of Outpatient Clinic of District 2, ASL RM6

³M.D, Nuclear Medicine department of Marino San Giuseppe Hospital, ASL RM6

⁴M.D, Director of the District 2, Director of Department of ASL RM6

Citation: Zarola F, Bartolomei R, Tiberio NS, Vassallo PL. Mixed Tremor in Parkinsonian Syndromes: A Study of Clinical Evolution and Treatment in Patients of Local Outpatients Parkinsons Disease and Movement Disorder Unit. *Am J Psychol & Brain Stud*, 2023;1(1):14-18.

Received: 01 July, 2023; **Accepted:** 19 July, 2023; **Published:** 03 November, 2023

***Corresponding author:** Flora Zarola, Director of the Unit of Parkinson's Disease and Movement Disorders 2 ASL RM 6, Albano Laziale, Rome, Italy, Tel: 3358290152; E-mail: florazarola@hotmail.it

Copyright: © 2023 Zarola F, et al., This is an open-access article published in Am J Psychol & Brain Stud and distributed under the terms of the Creative Commons Attribution License, which permits unrestricted use, distribution, and reproduction in any medium, provided the original author and source are credited.

A B S T R A C T

Aim: The aim of the study was to make a retrospective analysis of the symptom's evolution in subjects with uncertain diagnosis of Essential Tremor, Parkinson's disease, or other similar parkinsonisms, observing the efficacy of the therapeutic strategies adopted over time and to define possible therapeutic models with the support of instrumental analysis (scintigraphy, RM scan).

Methods: The medical histories of some of the patients who came to the clinic between 2017 and 2022 with the main complaining of tremor and in some cases with initial symptoms not absolutely attributable to Parkinson's disease, although with the dubious coexistence of a possible related extrapyramidal disease, were considered for the study. The clinical improvement of the symptom following the use of monotherapy and/or combined therapies for Essential Tremor and Parkinson' disease was noted, having excluded other types of tremors, such as dystonic/myoclonic, alcoholic or iatrogenic tremor. The UPDRS rating scale was used as part of the routine examination of outpatient movement disorders patients. In addition to clinical evaluation, other tests carried out were taken into account, such as the RM or TC brain scan and the DatScan.

Results: individual cases deserve a single analysis as they are particularly significant for the clinical evolution with respect to the growing sensitivity to the specific added dopaminergic therapy; overall, improving by combining the therapy for Essential Tremor and the dopaminergic therapy was often observed. In some patients a concomitant progression of cerebrovascular disease was detected with the increasing sensitivity to dopaminergic therapy, as described in Case report.

Conclusion: Tremor in the considered extrapyramidal diseases is a complex disorder, even in well-known conditions such as Essential Tremor, Parkinson's disease and other syndromic extrapyramidal frames, with necessary separate evaluation and treatment; its evolution over time and response to different drug therapies may be related to cerebrovascular disease. Indications' criteria as well as caution in drug contraindications and interactions are discussed in the selected clinical cases together with the instrumental results of DatScan.

Keywords: Cerebrovascular disease, Dopaminergic, GABA, parkinsonism, Parkinson's disease Essential Tremor, Therapy, tremor

1. Introduction

In daily routine the clinician has in duty the management of many patients' clinical conditions which have a significant

functional impact on the quality of life. One of these highly frequently occurring in the Movement Disorders Clinic (MDC) is tremor. Many patients undergo a visit complaining of this

symptom with apprehension both because of the impairment it causes in daily activities, and because in the collective reputation it is identified with the dreaded diagnosis of Parkinson's disease. Therefore, the treatment of tremor is a relevant topic and often worthy of a separate attention by the clinicians compared to the complex of other symptoms in extrapyramidal diseases. The diagnosis and treatment are not obvious, and often show an evolution over time that need repeated therapeutic evaluations and changes, being not simply linked to the correctness of the initial diagnosis. Often this symptom is instead considered strictly part of the syndromic picture, as for example in Parkinson's disease and its eventual improvement is considered, if possible, as a univocal consequence of the main therapy. Instead, clinical experience shows that a clear distinction between different types of tremors, caused by different pathogenic mechanisms can coexist or evolve into each other and therefore require an association of pharmacological therapies that can change in time depending on Modifying Sensitivity to different type of drugs.

2. Materials and Methods

A number of patients was selected among those taken in charge in the District MDC between 2017 and 2022 and their clinical histories were analyzed to be described in this study. Their peculiarity consists in the centrality of the tremor, which represents the main cause for which the patients came to the clinical evaluation, complaining the functional/psychological impact and interference on quality of life. The patients underwent to anamnesis and physical examination, including UPDRS part III and MMSE evaluation, according to a routine protocol; instrumental investigations, such as Rx, magnetic tomography scan (RM) of brain and spine, and [(123) I]β-CIT SPECT examination (DatScan). Clinical and instrumental investigations have excluded pathogenic causes of tremor such as alcohol or lead or other intoxication, as well as iatrogenic or trauma or cerebellar vascular/ degenerative/genetic lesions in the selected cases. The tremor was evaluated in the context of a suspected onset of an extrapyramidal disease like degenerative parkinsonism within the boundaries of possible Essential Tremor (ET), Parkinson's disease (PD), parkinsonisms such so-called Vascular Parkinsonism (VP) and/or Atypical Parkinsonism (AP).

Case 1: female aged 64 at the time of first access (2018, November), with a tremor of both hands which she complained while holding a cup or a glass, making the signature, or doing small movements; she had no hyposmia. The clinical examination showed normal gait, no evidence of plastic hypertonia, not hypomimia, tremor in Mingazzini test of both hands, with regular approximate frequency of 8-10 Hz, as well as in the forefinger-nose test, slightly more evident on left. A slight and infrequent tremor was barely visible in the left hand which faded into postural tremor due to the patient's difficulty in maintaining the state of relaxation of the limbs caused by anxiety. Persistent observation allowed to detect the grafting of postural and kinetic tremor on a very slight tremor at rest. The UPDRS score was 8, the MMSE score was 28. The score of the UPDRS was due to tremor, while no other extrapyramidal signs were detectable. An attempt of treatment with the beta-blocker propranolol 40mg 1/2 bis in die was made, after the approval of the cardiologist and with a definite improvement of patient's symptom. In the meanwhile, she underwent other investigations, like brain RM (2018, December) which showed "some small signal changes of the brain white matter referable to mild gliosis, and a fetal origin of the right posterior cerebral artery from the carotid siphon" a pulmonary visit which detected an Obstructive Sleep Apnea Syndrome (OSAS) without indication to C-PAP prescription.

In a subsequent visit an attempt with a low dosage of dopaminergic therapy (L-Dopa 100mg bis in die) was associated to the beta blocker, which was adopted with caution due to respiratory disease; on the other hand, the patient reported satisfaction for further improvement, but was reluctant to stop the beta blocker because of the improvement. She therefore underwent the DatScan examination (2019, January), which showed: "slight reduction in visualization of putamen and caudate nuclei. Specific/nonspecific uptake ratio shows slightly altered receptor imaging". With the combined therapy the UPDRS score resulted 4; in 2021, January a control RM brain scan showed: "presence of areas of tissue necrosis on an ischemic cerebrovascular basis expression of lacunar infarcts, with evolutionary picture compared to the previous examination performed". The imaging showed a worsening of diffuse cerebrovascular disease. For a slight worsening of the tremor, the dosage of L Dopa 100mg was increased to 3 tablets per day and testing for genetic mutations related to thrombophilia due to elevated homocysteine was requested, without other vascular risk factors; the result was homozygous MTHFR mutation type C677T and heterozygous Leyden V factor. The patient was already on antiplatelet therapy and folate was added. The latest UPDRS score recorded was 16, MMSE score 27.9 (2023, January), still managing the tremor with a combination of low dosages of propranolol and L-dopa.

Case 2: female patient 55 yrs. old born in Romania, affected by epilepsy at a young age and free from seizures for many years, without therapy. No vascular risk factors, no anosmia, no gait impairment was observed; she had suffered for many years from untreated depressive syndrome, caused by family problems including the death of a daughter. Since about 7 years before, she had developed a tremor in her upper limbs, for which she didn't receive treatment. Clinical examination showed slight hypomimia, which could be likely attributable to the affective flattening of depression, no plastic hypertonia was evident. Tremor was shown in dynamic maneuvers with slight onset 'at rest' in the right hand. UPDRS in 2018, November, was 12. The first attempt of treatment was done with beta blocker propranolol, 40mg 1/4 of dosage in four administrations/die after approval of the cardiologist; she showed an improvement, while investigations were going on, like brain RM and DatScan. Brain RM resulted normal (2018, November). In a control examination a small dose of dopaminergic therapy was added, consisting in rotigotine patch 4 mg/die; the patient showed an improvement, also with regard to the depressive syndrome. The DatScan showed: "Inhomogeneous visualization of both striatum. The specific/nonspecific uptake ratio obtained by analysis with the regions of interest shows lower than normal values. Slightly altered receptor imaging" (2019, February). The dosage of rotigotine was subsequently increased to 6 mg in combination with propranolol, with improvement both of tremor and depressive syndrome.

Case3: female patient 70 yrs. old (2018, October). at first clinical evaluation. She had undergone surgery for lumbosacral spine stenosis a few years earlier, and was suffering from depressive syndrome, balance disorders with falls, thyroid goiter in replacement therapy, heart disease. Moreover, she suffered from COPD with beta-receptors stimulating therapy. The onset of the tremor had occurred a few months earlier, and affected the head (like "no"). The classic plastic hypertonia was not evident; she suffered from a gait impairment apparently attributable to rachis stenosis and gonarthrosis, while there was no tremor in the limbs or hypokinesia, while there was a slight but visible tremor of the head like "no" with regular relatively high frequen-

cy (8-Hz). The UPDRS score was 21, MMSE 27.3. A test with 100 mg dose of L-dopa (me-levodopa) to detect any positive response, without significant change in the UPDRS score within 1 h was performed at that stage. The first presumptive diagnosis was TE but the DatScan was requested. The propranolol therapy was contraindicated due to COPD and the concomitant use of beta blocker therapy; however, attribution of tremor to beta stimulant drug use was unlikely. The DatScan report was (2019, March): “slight reduction in visualization of the putamen; slightly altered receptor brain imaging”. A brain MRI dated November 2018 showed “multiple foci of reparative gliosis attributable to ischemic micro vascular outcomes in the frontal site bilaterally”. The patient showed improvement of head tremor and of motor impairment with dopaminergic patch therapy (rotigotine) in a progressively increased dose up to 8 mg, in association with antidepressant therapy. A DatScan was repeated in 2022, October: “the scintigraphy study shows a very slight reduction of the uptake of the putamen, greater on the left. Altered receptor imaging due to reduced functional activity of the putamen, more evident on the left”. In clinical follow-up examinations the patient showed a definite improvement of head and upper limbs tremor and partially of depression, while this was not evident for the gait, which was attributed to spine interventions and gonarthrosis. In the meantime, the patient had developed a Restless Legs Syndrome, which benefited from the same dopaminergic therapy.

Case 4: Woman 73 yrs. old in first examination, (2017, June.) She complained of tremor of the head and hands, in family history an older sister affected by m. of Parkinson in dopaminergic therapy is reported. The tremor had been increased since few months and was more evident on head and the right-side limb. She suffered from tubercular pleurisy at a young age, she had subsequently developed severe COPD, for which she was followed up in a pulmonology department and had regular chest CT scans and was under medication. The UPDRS score was 26, mostly due to postural and kinetic tremor of upper limbs and head tremor, MMSE was 24. The test of spiral drawing excluded dyskinesia. Cardiologist’s examination did not exclude the use of beta blocker; however, the request for a favorable opinion from the pulmonologist gave a negative result, due to the bronchus-obstruction and the presence of pulmonary nodules. An attempt was done with gabapentin 100mg bis in die with improvement and successively low doses of L-dopa (100mg bis in die). The DatScan showed (2017, October) specific/non-specific uptake ratio normal, and absence of impairment of the dopaminergic system; however, the combination therapy with low doses of dopamine was maintained due to the positive response shown (UPDRS score 18) and the finding of a global improvement in daily activities reported by the patient, with recovery of quality of life. A control of DatScan will be probably scheduled. All the patients in description did not show evident or prominent impairment of voluntary gaze (**Figure 1**).

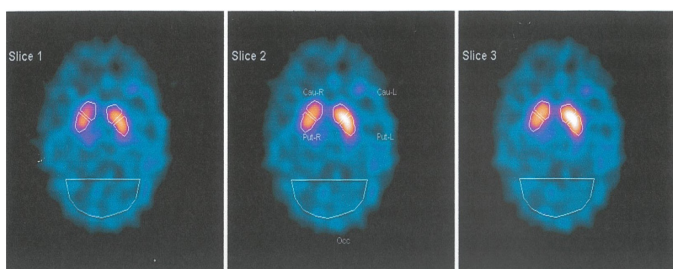


Figure 1. Clinical case 1: patient with MTHFR mutation type C677T and heterozygous Leyden V factor and cerebral vasculopathy. Brain [(123I)-CIT] SPECT examination (DatScan) 2019, January; first access to outpatient clinic, 2018, November.

3. Results

The patients’ cases reported show frequent situations in routine practice in which a set of common and well-known drugs is useful for neurologists on the basis of clinical observation, sometimes in apparent contrast with some evidences of instrumental investigations: low-dose dopaminergic therapies, beta blockers, gabaergic drugs were mainly used, taking into account underestimated contraindications, such as COPD along with heart rhythm disturbances for the use of beta-blockers. In several clinical cases, like the ones taken as a sample, the efficacy of associating dopaminergic therapy was noted, despite the scarce or absent evidence of alteration of pre-synaptic dopaminergic system at the DatScan. On the contrary, some patients took advantage of association of propranolol to dopaminergic therapy although the definite propensity of DatScan result for Parkinson’s disease diagnosis (**figure 2**).

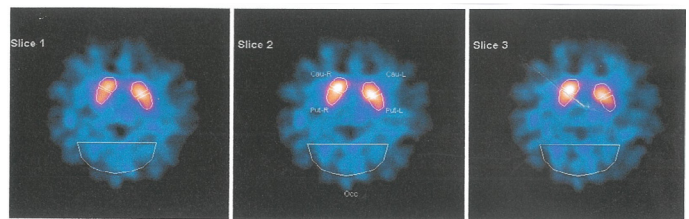


Figure 2. Clinical case 2: DatScan , 2019, February. First access to clinic in 2018, October. The analysis report describes “specific/non-specific uptake ratio in the region of interest lower than normal values, slightly altered receptor imaging”

4. Discussion

Tremor is a complex disorder, even in well-known conditions such as ET, PD, VP, AP and other syndromic extrapyramidal frames. Clinicians are often involved in the first examination with patients affected particularly complained, contrary to other type of onset symptoms in extrapyramidal and degenerative diseases, such as mood disorders or gait disturbances. Therefore, in order to enable specialists to give a prompt relief to the urgent patients’ request for improvement of the quality of life, tremor is object of specific accuracy and treatment.

Subcortical Tremor is a disorder in which different neurotransmitters and brain circuitries impairment are known to be involved¹. The main role of dopaminergic pathways is clinically summoned to account for symptoms including the typical tremor in PD, while different considerations have been defined for Essential and ‘senile’ tremor: in those cases, a prevalent gabaergic basis has been recognized¹⁻² (**Figure 3**) The relevance of GABA as a neurotransmitter of the striatum, besides dopamine and other neurotransmitters of the same structure and other subcortical sites, like brainstem and cerebellum, is certain². Subcortical networks including cerebellar pathways, are involved in movement and tremor disorders, as described for instance in Holmes tremor, in which brainstem circuitries like the” myoclonus triangle “(dentate-rubral-olivarian pathway, i.e., the Guillain-Mollaret Triangle) are an important feedback circuit of the brainstem and deep cerebellar nuclei responsible for the modulation of motor activity in the spinal cord³. In the Authors’ clinical experience of the District MDC as well as in literature there is a frequent observation of symptomatic combinations such as the coexistence of rest and postural/kinetic tremor, or the localization at the head of tremor responsive to dopaminergic drugs, or tremor’s higher frequency with low expectancy of response to dopaminergic therapy which showed improvement instead. These observations in clinical routine practice are coherent with the known studies relating to the evolution of TE in PD or to their coexistence in genetic or familial form, in some cases with dystonic syndromes, Essential Tremor

Plus, or Essential Tremor-Parkinson's Disease⁴⁻⁸. Other recent studies have also highlighted a variability of associations and/or subtypes of tremor in PD^{1-2, 9}. In many cases in the present study the usefulness of DatScan analysis resulted remarkable to support the use of dopaminergic therapy when the frequency and location of the tremor, as in the clinical cases described 1,2, and 3, generated great uncertainty about the nature of the tremor and the prediction of the response to various drugs - combined or not. However, in other cases, exemplified with the clinical case 4, a good efficacy of dopaminergic therapy is found even in the absence of an evident compromise of the DatScan; similar conditions may correspond to a preclinical phase of the degeneration of the dopaminergic system, already clinically sensitive to low doses of dopaminergic therapy, and possibly susceptible to future modifications of the scintigraphy picture in a full-blown phase of degeneration of the dopaminergic system; for this reason the follow-up methods over time predict utility of [(123)I]β-CIT SPECT control. However, clinical cases 1 and 2 showed slight alterations of Dat Scan, and in clinical case 3 this finding was persistent along time (see reports of 2019, (March and 2022, October). Moreover, in clinical case 1 there was an evolution of cerebrovascular disease (CVD) in time, preceding the antiplatelet therapy, due to the diagnosed genetic thrombophilia (and possibly to COPD); in this case we observed an onset with clinically evident non-familial ET shifting increasingly to a more definite response also to dopaminergic therapy, which progression was consistent with other studies on the role of CVD in PD : in fact, frequent clinical observations in the District MDC.

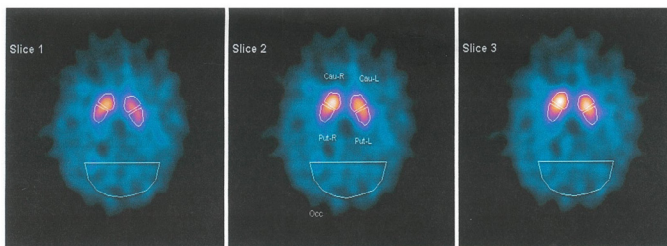


Figure 3a: clinical case 3: DatScan of 2019, March, with "slightly altered receptor brain imaging" described in the report. A test with L-Dopa performed in the first access, 2018 October was negative (head tremor, slight hands tremor)

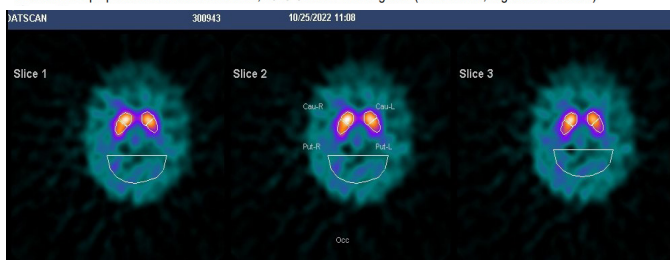


Figure 3b: clinical case 3: control DatScan of 2022 October with report description: "very slight reduction of the uptake of the putamen, more evident on the left; altered receptor imaging with reduced functional activity of the putamen, more evident on the left"; N.B. the tremor was improved with combined therapy, not the gait (see the text).

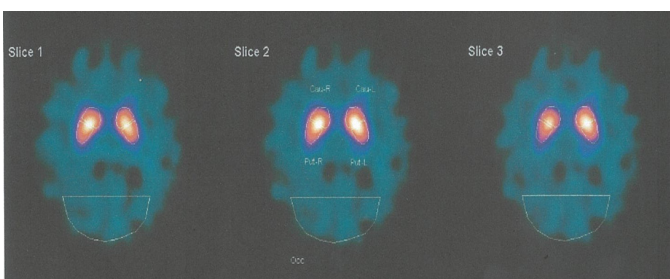


Figure 4: clinical case 4: Dat Scan 2017 October. The report showed "absence of impairment of the dopaminergic system". The patient's tremor was treated with combined GABAergic and low dosed

dopaminergic drugs with improvement (see text) envisaged that evolution of tremor, as well as other parkinsonian symptoms, may be related to CVD lesion load worsening (as well as to strokes) and may require significant changes in therapy⁹⁻¹².

5. Conclusions

Based on these clinical cases' observations, it is worthy to make further studies to define criteria for prevention and improvement in life quality expectancy on large patients' populations. While evaluating characteristics of tremor in subjects with poor other extrapyramidal signs like suspected Essential Tremor and/or uncertain diagnosis, it is appropriate to verify the partial conversion to the efficacy of dopaminergic therapy over time, with the support of DatScan analysis. On the other hand, in many cases there is a discrepancy between the successful clinical outcomes of the drugs used with initial some degree of uncertainty and the results of the instrumental analysis, which are not due to technical bias. In not infrequent conditions with 'mixed' susceptibility to combined therapies of tremor a progressive increasing efficacy of dopaminergic drugs has been observed, despite without big changes in DatScan; this situation could be paired to the 'transition' from Essential Tremor to Parkinson's Disease described in literature. In many cases there is a good success with combined therapies like gabaergic, beta-blocker and dopaminergic drugs dose-balanced in single cases with modifications during time. Interestingly, the conversion to dopaminergic therapy can be observed concurrently with the increasing cerebrovascular lesion load.

6. Acknowledgments

The Authors wish to thank the nurse coordinator Francesco Pepe, Mrs Marina Taddei, the staff of the 2nd District of ASL RM6, and the staff of Nuclear Medicine of San Giuseppe Hospital of Marino.

7. References

1. Dirx MF, Bologna M. The pathophysiology of Parkinson's disease tremor. *Journal of the Neurological Sciences* 2022,435:120196.
2. Den Berg KRE van, Helmrich RC. The Role of the Cerebellum in Tremor - Evidence from Neuroimaging. *Tremor other Hyperkinet Mov (N Y)* 2021,11:49.
3. Murdoch S, Shah P, Jampana R. The Guillain–Mollaret triangle in action. *Practical Neurology* 2016,16.3:243-246.
4. Louis ED, Hernandez NC, Ottman R. Mixed Motor Disorder: Essential Tremor Families with Heterogeneous Motor Phenomenology. *Neurol Clin Pract* 2021,11(6):e817-e825.
5. Du W, Bain PG, Defazio G, Jankovic J, Kim CY, et al., The Conundrum of Dystonia in Essential Tremor Patients: How does One Classify these Cases? *Tremor Other Hyperkinet Mov (N Y)* 2022,13:12-15.
6. Bellows ST, Jankovic J. (2021) Phenotypic Features of Isolated Essential Tremor, Essential Tremor Plus, and Essential Tremor-Parkinson's Disease in a Movement Disorders Clinic. *Tremor Other Hyperkinet Mov (N Y)* 2021,11:12.
7. Ryu DW, Lee SH, Oh YS, A JY, Park JW. Clinical Characteristics of Parkinson's Disease Developed from Essential Tremor. *J Parkinsons Dis* 2017,7:2:369-376.
8. Song IU, Park JW, Chung SW, Chung YA. Brain SPECT can differentiate between essential tremor and early-stage tremor-dominant Parkinson's disease. *J Clin Neurosci* 2014,21:9:1533-7.
9. Michiel F, Dirk X, Heidemarie Z, Bastiaan R. Bloem, et al., The nature of postural tremor in Parkinson disease. *Neurology* 2018,27: 90(13):e1095–e1103.

10. Zarola F. Incidence of Brain Vascular Damage in a Population with Parkinson's Disease: Statistical Comparison by Age Subassemblies with Age Homogeneous Control Groups. *Cureus*. 2020,12(6):e8778.
11. Zarola F. Brain Vascular Damage in Essential Tremor: Observational Study and Statistical Analysis in An Affected Population Compared with A Group with Parkinsons Disease and A Control Group. *Journal of Psychiatry and Psychiatric Disorders* 2019,3(2):031-036.
12. Zarola F. Vascular Parkinsonism: A Clinical Study of Response to Dopaminergic Therapy and Patterns of Brain Vascular Lesions in a Group of Patients. *Insights of Neuro Oncology* 2022,5(1)51-53.