

World Journal of Surgery and Surgical Case Reports

<https://urfpublishers.com/journal/surgery-and-surgical-case-reports>

Vol: 1 & Iss: 2

Is There A Subgroup of Kinking

Aymer Cosar¹, Kadir Yildirim² and Mehmet Erkan Ustun^{3*}

¹Department of Neurosurgery, Yenimahalle Training and Research Hospital, University of Yildirim Beyazit, Ankara, Turkey

²Department of Neurosurgery, Kafkas University, Turkey

³Department of Neurosurgery and Anatomy, Private Clinic, Ankara, Turkey

Citation: Cosar A, Yildirim K, Ustun ME. Is There A Subgroup of Kinking. *World J Surg Surgical Case Rep*, 2025;1(2):57-60.

Received: 25 August, 2025; **Accepted:** 05 September, 2025; **Published:** 08 September, 2025

***Corresponding author:** Mehmet Erkan Ustun, Department of Neurosurgery and Anatomy, Private Clinic, Ankara 06010, Turkey, E-mail: merkanustun@hotmail.com

Copyright: © 2025 Ustun ME, et al., This is an open-access article published in World J Surg Surgical Case Rep and distributed under the terms of the Creative Commons Attribution License, which permits unrestricted use, distribution, and reproduction in any medium, provided the original author and source are credited.

ABSTRACT

Vertebral and carotid artery kinking which are categorized inside dolicoarteriopathies, linked to various cerebrovascular dysfunctions. Moderate and severe kinking reduced blood flow, contributing to hemodynamic instability and cerebrovascular insufficiency. While most symptomatic cases undergo endovascular or surgical correction, some patients with severe kinking remain asymptomatic, questioning current understanding. In over 120 cases of carotid or vertebral artery kinking, we observed stenosis in symptomatic patients, differing from the expected arterial enlargement seen in dolicoarteriopathies. This suggests two potential kinking types: stenotic and enlarged.

Keywords: Dolicoarteriopathies, Kinking, Carotid artery, Vertebral artery, Vertebrobasilar insufficiency, Cerebrovascular insufficiency

1. Kinking

Vertebral artery and carotid artery kinks are classified according to Metz et al., Grade 1: 90-60 degrees (mild kinking), Grade 2: 60-30 (moderate kinking), Grade 3: < 30 degrees (severe kinking)¹⁻³. Especially, in moderate and severe kinking, there is a reduction in blood flow, which escalates the risk of ischemic events⁴. Such vascular anomalies can lead to hemodynamic disturbances and are implicated in vertebrobasilar and cerebrovascular insufficiency pathophysiology. Endovascular or surgical procedures are tailored to address these kinkings, offering alternative avenues for restoring cerebral hemodynamics and alleviating the associated neurological symptoms⁵⁻⁷.

However in clinical practise most of us have seen that some patients with grade 2 or 3 kinking have no neurological symptoms. After operating over 120 cases due to carotid or vertebral artery kinking we have observed that in all of these symptomatic

cases, the kinking area was stenotic. All surgeries were performed by the senior surgeon (M.E.U), with informed consent obtained from all participants. The local ethics committee approved the study, documented under approval number 2/12 dated 03.30.2022. From the literature we know that in dolicoarteriopathies the arteries are enlarged even in kinking cases. But in our cases they were stenotic. Therefore in our operations we used a technique that has been used for the first time in kinking. After arteriolysis (releasing the artery from surrounding fibrotic tissue and thickened adventitia) we cut the sympathetic fibers around the vessel under microscopic magnification which we named as perivascular sympathectomy⁸⁻¹¹ (Figure 1A and 1B). The dilatation of the vessel with this technique showed us that the main pathology was outside the vessel (Figure 2A and 2B). This observation raises an important question do kinkings have two types as stenotic and enlarged/normal diameter or in other

terms as symptomatic and asymptomatic, where the stenotics are symptomatic. Before operation beside brain Magnetic Resonance (MR) and MR angiography, we also obtained cervical MR/Computed Tomographic (CT) angiography (Figure 3A and 3B) and also postoperatively (Figure 4A and 4B). We also obtained brain CT /MR perfusion images pre and postoperatively. (Figure

5A and 5B). During the operation after arteriolysis, the stenosis at the kinking artery become more apparent than the Magnetic Resonance (MR)/Computed Tomographic (CT) angiography. The perfusion studies showed mild to moderate hypoperfusion at the kinking side with stenosis, but was normal postoperatively (Figure 6A,B and C,D).

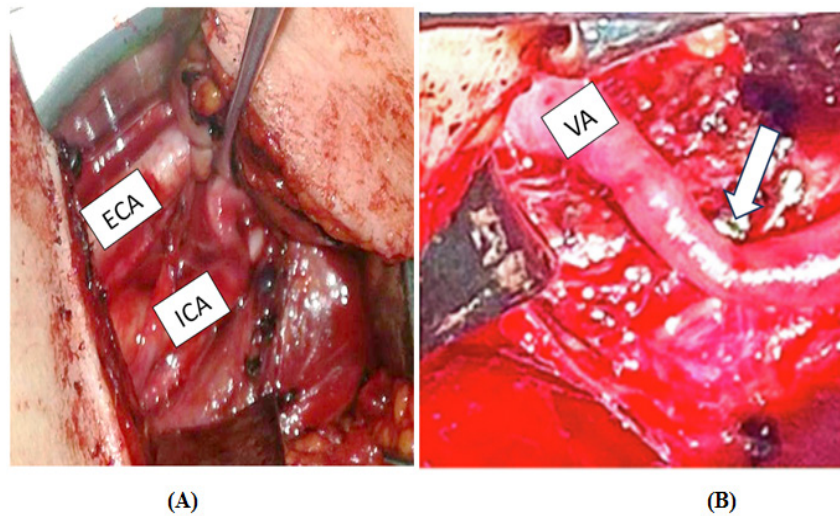


Figure 1A: Intraoperative view; White arrow shows the stenotic left internal carotid artery (ICA) when compared with external carotid artery (ECA).

Figure 1B: Intraoperative view; White arrow shows the stenotic left vertebral artery (VA).

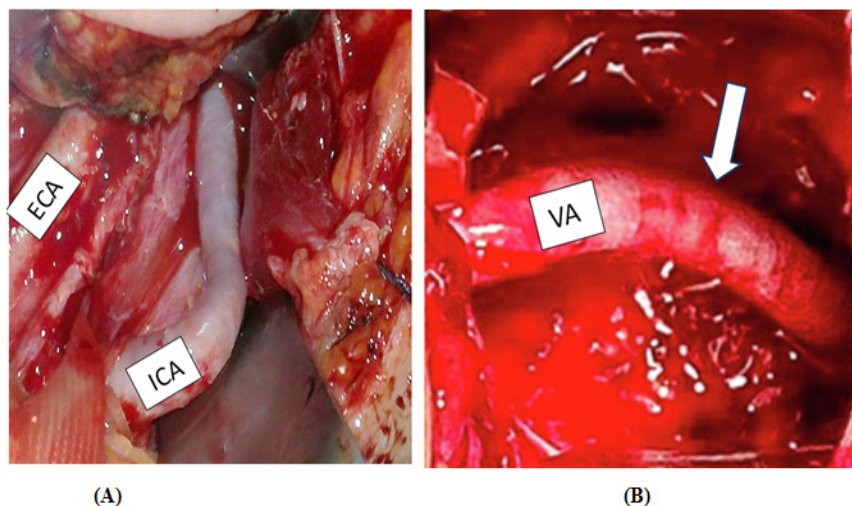


Figure 2A: Intraoperative view; After perivascular sympathectomy the left internal carotid artery (ICA) is enlarged and its diameter is approximately the same with external carotid artery (ECA).

Figure 2B: Intraoperative view; After perivascular sympathectomy the left vertebral artery (VA) is enlarged.

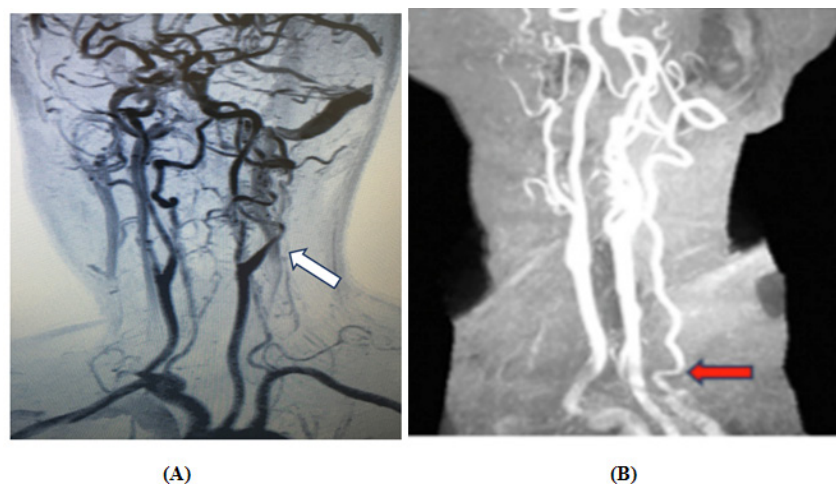


Figure 3A&B: Preoperative magnetic resonance (MR) angiography; White arrow shows the stenotic segment.

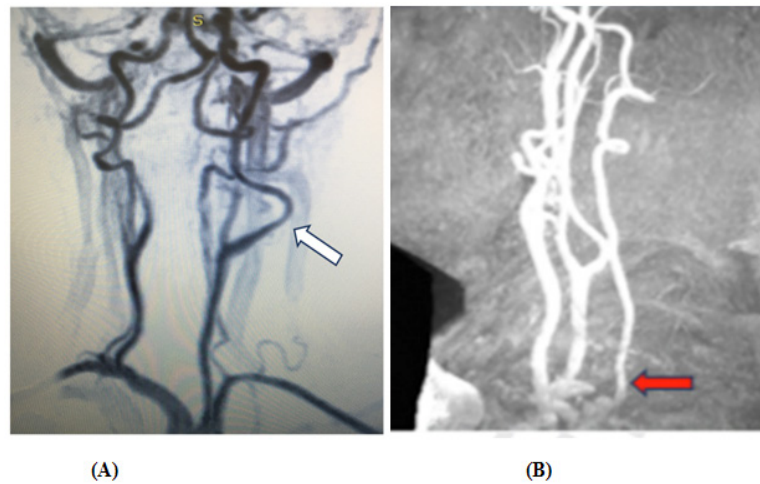


Figure 4A&B: Postoperative magnetic resonance (MR) angiography; White arrow shows the dilated segment after perivascular sympathectomy.

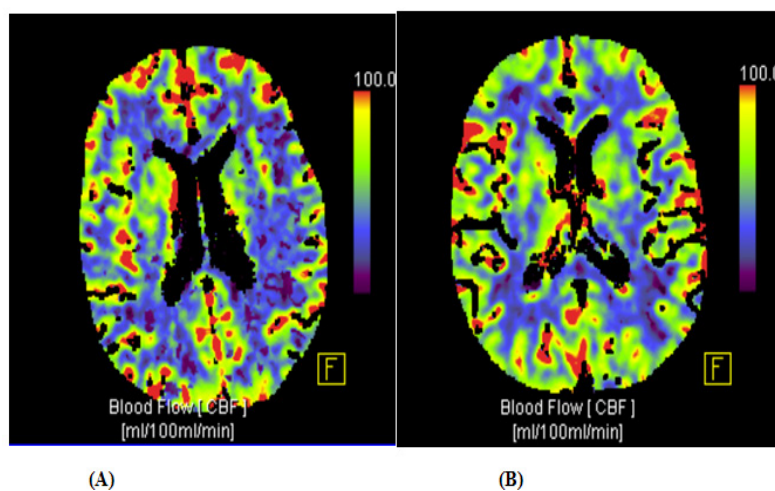


Figure 5A: Preoperative brain perfusion computed tomography; White arrow shows the frontoparietal hypoperfusion area.

Figure 5B: Postoperative brain perfusion computed tomography; White arrow shows the disappearance of the hypoperfusion area.

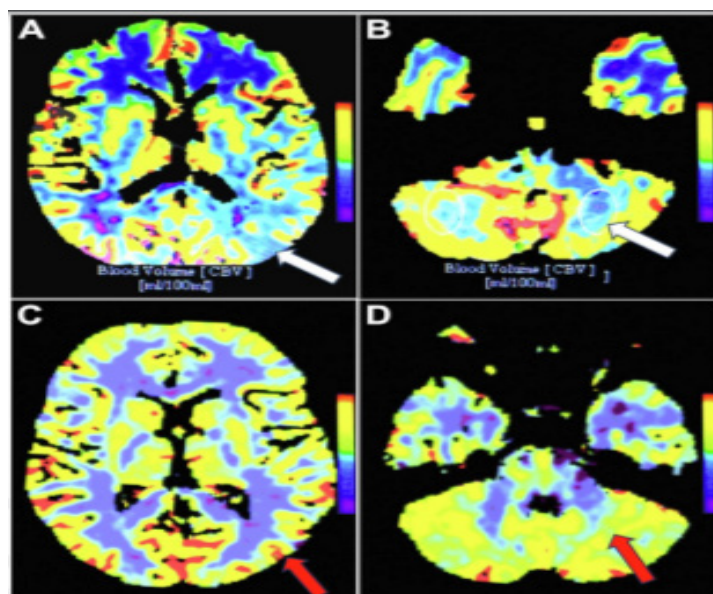


Figure 6A: Preoperative brain perfusion computed tomography; White arrow shows the left occipitoparietal (posterior watershed zone) hypoperfusion area.

Figure 6B: Preoperative brain perfusion computed tomography; White arrow shows the left cerebellar hypoperfusion area.

Figure 6C: Postoperative brain perfusion computed tomography; Red arrow shows the disappearance of the left occipitoparietal (posterior watershed zone) hypoperfusion area.

Figure 6D: Postoperative brain perfusion computed tomography; Red arrow shows the disappearance of the left cerebellar hypoperfusion area.

2. Conclusion

Our observations challenge the prevailing understanding that kinking primarily involve arterial enlargement. In a series of 120 cases, we found that symptomatic patients often exhibited arterial stenosis at the kinking site, which were corrected with a new technique named as perivascular sympathectomy, suggesting the existence of two distinct types of kinking: stenotic and enlarged. Grading of the kinking as grade 2 or 3 may worsen the symptoms if they are stenotic. These results highlight the need for re-evaluating the clinical approach to dolicoarteriopathies, particularly regarding the differentiation of kinking types and suggest a potential shift in treatment strategies based on hemodynamic profiles rather than anatomical classification alone.

3. References

1. Eksi MS, Toktas ZO, Yilmaz B, et al. Vertebral artery loops in surgical perspective. *Eur Spine J.* 2016;25: 4171-4180.
2. Omotoso BR, Harrichandparsad R, Moodley IG, et al. An anatomical investigation of the proximal vertebral arteries (V1, V2) in a select South African population. *Surg Radiol Anat.* 2021;43: 929-941.
3. Metz H, Bannister RG, Murray-Leslie RM, et al. Kinking of the internal carotid artery. *The Lancet.* 1961;277: 424-426.
4. Wang J, Lu J, Qi P, et al. Association between kinking of the cervical carotid or vertebral artery and ischemic stroke/tia. *Front Neurol.* 2022;13.
5. Lu X, Ma Y, Yang B, et al. Hybrid technique for the treatment of refractory vertebrobasilar insufficiencies. *World Neurosurg.* 2017;107: 1051.
6. Starke RM, Chwajol M, Lefton D, et al. Occipital artery-toposterior inferior cerebellar artery bypass for treatment of bilateral vertebral artery occlusion. *Neurosurgery.* 2009;64: 779-781.
7. Rennert RC, Steinberg JA, Strickland BA, et al. Extracranial-to-Intracranial bypass for refractory vertebrobasilar insufficiency. *World Neurosurg.* 2019;126: 552-559.
8. Cekic E, Baylarov B, Surme MB, et al. Collateral gains from vascular microsurgical intervention on the V1 segment dolicoarteriopathy of the vertebral artery: alleviating restless leg syndrome and urgency urinary incontinence symptoms in refractory vertebrobasilar insufficiency cases. *J Clin Neurosci.* 2025;138: 111369.
9. Cekic E, Surme MB, Akbulut F, et al. Secondary Benefits of Microsurgical Intervention on the Vertebral Artery (V1 Segment) for Refractory Vertebrobasilar Insufficiency: Alleviation of Parkinsonism-Like Symptoms. *World Neurosurg.* 2024;187: 551-559.
10. Cekic E, Ustun ME. Adventitia Layer-Focused Microsurgical Flow Reconstruction for Long-Segment Tubular Stenosis of the Cervical Segment (C1) Internal Carotid Artery: Clinical Valuable Experience in 20 Cases. *Brain Sci.* 2024;14(3): 289.
11. Pinar E, Baylarov B, Cekic E, et al. Clinical Outcomes of Microsurgical Flow Reconstruction in Long-Segment Cervical ICA Stenosis with Distal Grade 2 or 3 Kinking. *World Neurosurg.* 2025;201: 12481.