






Cystic Hidradenoma Presenting as a Chronic Aural Polyp: A Rare Ceruminous Gland Tumour of the External Auditory Canal

David J.R. Dillard, BS^{*}, Colten L. Witte, BS^{}, Andrew C. Norred, BS^{}, Kenneth J. Walton, BS^{}, Joshua Rapp, BS^{}, Lynn D. Cooper, MD, James K. Fortson, MD and Nathan Douthit, MD

Sleep and Sinus Centers of Georgia, Lawrenceville, GA, USA

Citation: Dillard DJR, Walton KJ, Norred AC, et al. Cystic Hidradenoma Presenting as a Chronic Aural Polyp: A Rare Ceruminous Gland Tumour of the External Auditory Canal. *Medi Clin Case Rep J* 2026;4(1):1556-1559. DOI: doi.org/10.51219/MCCRJ/David-JR-Dillard/429

Received: 27 December, 2025; **Accepted:** 30 December, 2025; **Published:** 02 January, 2026

***Corresponding author:** David J.R. Dillard, B.A. Sleep and Sinus Centers of Georgia, 1990 Riverside Pkwy, Lawrenceville, GA 30046, USA

Copyright: © 2026 Dillard DJR, et al., This is an open-access article distributed under the terms of the Creative Commons Attribution License, which permits unrestricted use, distribution, and reproduction in any medium, provided the original author and source are credited.

ABSTRACT

Cystic hidradenoma is a benign sweat gland tumor that very rarely arises in the external auditory canal and represents an uncommon subtype of ceruminous gland neoplasms. Owing to its low prevalence and nonspecific presentation, it is frequently misdiagnosed as chronic inflammatory ear disease, leading to delays in definitive diagnosis. We describe the case of a 32-year-old male who presented with several months of persistent unilateral otorrhea, aural fullness and conductive hearing loss refractory to multiple courses of topical and systemic therapy. Otoscopic examination demonstrated granulation tissue with a polypoid mass obstructing the external auditory canal, raising concern for chronic otitis externa, inflammatory aural polyp or neoplastic pathology. Computed tomography of the temporal bone showed a soft tissue lesion confined to the external auditory canal without bony erosion or middle ear involvement. Because symptoms persisted despite appropriate medical therapy, surgical excision was performed. Histopathologic evaluation revealed a benign cystic hidradenoma characterized by cystic architecture and adnexal differentiation without cytologic atypia or malignant features. The postoperative course was uncomplicated, with resolution of otorrhea, improvement in hearing and no evidence of recurrence at six-month follow-up. This case highlights the diagnostic challenge posed by rare ceruminous gland tumors and emphasizes the importance of early biopsy or excision in refractory unilateral external auditory canal disease, as surgical resection remains both diagnostic and definitive management.

Keywords: Cystic hidradenoma; Ceruminous gland neoplasms; Chronic otitis externa; Inflammatory aural polyp

Introduction

Ceruminous gland tumors of the external auditory canal are rare, accounting for a small fraction of neoplasms arising in this anatomic region. These tumors originate from modified apocrine sweat glands located within the cartilaginous portion of the external auditory canal and include a spectrum of benign and malignant entities¹. Among these, cystic hidradenoma represents

an exceptionally uncommon benign adnexal neoplasm, with only isolated cases reported in the literature¹⁻⁴.

Due to their rarity and lack of distinguishing clinical features, ceruminous gland tumors are frequently misdiagnosed as chronic inflammatory ear disease. Patients often present with nonspecific symptoms such as persistent otorrhea, aural fullness, canal obstruction, granulation tissue, polypoid masses and conductive

hearing loss, all of which overlap substantially with more common conditions including chronic otitis externa, chronic suppurative otitis media and inflammatory aural polyps^{3,5,6}. As a result, prolonged courses of topical or systemic antimicrobial therapy are often pursued, delaying definitive diagnosis^{2,3}.

The differential diagnosis for refractory external auditory canal polyps is broad and includes inflammatory polyps, keratosis obturans, benign neoplasms such as papilloma, ceruminous adenoma, pleomorphic adenoma and adnexal tumors, as well as malignant processes including squamous cell carcinoma and ceruminous adenocarcinoma^{4,7-9}. Given the potential morbidity associated with missed neoplastic disease, persistent unilateral canal pathology that fails appropriate medical therapy should prompt early tissue diagnosis through biopsy or complete excision^{7,8}.

Histologically, cystic hidradenoma is characterized by a well circumscribed lesion composed of solid and cystic components with adnexal differentiation. Typical findings include bland epithelial cells, occasional clear cell change, papillary architecture and absence of cytologic atypia or invasive growth, features that distinguish benign hidradenoma from malignant ceruminous tumors^{2,10-12}.

The existing literature on cystic hidradenoma remains limited to case reports and small series, with no standardized diagnostic or surveillance guidelines^{1,3,8,13}. Surgical excision is generally considered definitive treatment, with recurrence uncommon when complete resection is achieved^{1,12,14,15}. This case illustrates how cystic hidradenoma may masquerade as chronic inflammatory ear disease and underscores the importance of maintaining neoplastic etiologies in the differential diagnosis of refractory unilateral external auditory canal lesions.

Report of Case

A 32-year-old male with a history of developmental delay and mutism presented to an outpatient otolaryngology clinic with a long-standing history of persistent left-sided ear discharge and progressive hearing impairment. According to caregivers, the patient had experienced chronic unilateral otorrhea for approximately one year. During this time, he had been treated intermittently for presumed chronic otitis media with multiple courses of topical and oral antibiotics, which resulted in only temporary or minimal improvement. There was no reported history of prior otologic surgery, trauma or known neoplastic disease. His symptoms were confined to the left ear, with no associated vertigo, facial weakness or constitutional symptoms reported.

On presentation, otoscopic examination of the left ear demonstrated copious purulent otorrhea and friable granulation tissue filling the external auditory canal and completely obscuring visualization of the tympanic membrane. The right external auditory canal and tympanic membrane were normal. Audiologic evaluation confirmed a conductive hearing loss on the left side, consistent with mechanical obstruction of the external auditory canal. Given the chronicity of symptoms, unilateral presentation and presence of polypoid granulation tissue, the differential diagnosis included chronic suppurative otitis media with an aural polyp, cholesteatoma and neoplastic etiologies of the external auditory canal^{4,8,9,16,17}. Due to the refractory nature of the disease despite appropriate medical therapy, operative evaluation was

recommended. (Table 1) summarizes the differential diagnoses of refractory external auditory canal polyps.

Table 1: Differential diagnosis of refractory external auditory canal polyps, highlighting the overlap between inflammatory and neoplastic etiologies.

Entity	Typical Features	Distinguishing Considerations
Chronic suppurative otitis media with aural polyp	Chronic otorrhea, granulation tissue	Often associated with middle ear disease or cholesteatoma
Chronic otitis externa	Canal edema, erythema, discharge	Usually, diffuse inflammation rather than discrete mass
Cholesteatoma	Persistent otorrhea, conductive hearing loss	Often associated with bony erosion
Ceruminous adenoma	Slow-growing canal mass	Benign glandular tumor
Cystic hidradenoma	Polypoid canal lesion, obstruction	Diagnosis requires histopathology
Squamous cell carcinoma	Pain, bleeding, ulceration	Often aggressive, may show bone destruction

The patient was taken to the operating room for examination under general anesthesia. Endoscopic inspection of the left external auditory canal revealed a large mass of friable polypoid tissue arising from the anterosuperior quadrant of the tympanic membrane and extending to fill the canal lumen. The lesion was excised in its entirety via a transcanal approach. Intraoperatively, there was no evidence of ossicular erosion, middle ear cholesteatoma or deeper extension of disease and the middle ear space was not entered. The procedure was limited to the external auditory canal and superficial surface of the tympanic membrane. The patient tolerated the procedure well and no intraoperative complications occurred.

Histopathologic examination of the excised specimen demonstrated a cystic hidradenoma (nodular hidradenoma), confirming a benign ceruminous sweat gland tumor arising from the external auditory canal. The lesion exhibited both solid and cystic components composed of bland epithelial cells with clear cytoplasm and papillary architecture. No cytologic atypia, increased mitotic activity or malignant features were identified and surgical margins were free of tumor (Figure 1).

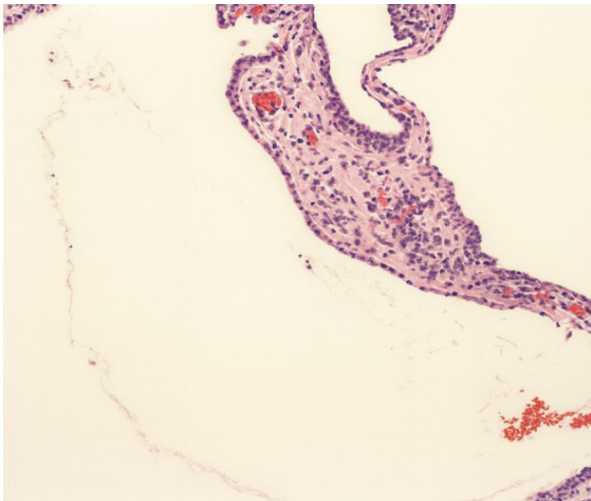


Figure 1: Histopathologic section of the external auditory canal mass. The tumor displays a cystic and papillary architecture with a two-layered epithelium, consisting of an inner layer of columnar cells and an outer layer of cuboidal cells. These features are consistent with an apocrine gland neoplasm (hidradenoma).

Postoperatively, the patient's recovery was uncomplicated. At follow-up visits, the left external auditory canal demonstrated appropriate healing and the tympanic membrane remained intact with a small scar at the excision site. The chronic otorrhea had completely resolved and subjective improvement in hearing was reported. At six-month follow-up, there was no evidence of recurrent disease on otoscopic examination. Given the rarity of ceruminous gland tumors and the potential, albeit low, risk of recurrence, the patient continues to be monitored with periodic clinical surveillance.

Discussion

The case presented above underscores the diagnostic challenge posed by rare ceruminous gland tumors of the external auditory canal, particularly when clinical findings overlap with more common inflammatory ear diseases. Chronic otorrhea with associated granulation tissue or aural polyps is most frequently attributed to inflammatory etiologies such as chronic suppurative otitis media or chronic otitis externa. Consequently, neoplastic causes may not be initially considered, leading to prolonged medical management and delayed tissue diagnosis.

As illustrated in Table 1, several clinical features in this case were more consistent with a neoplastic rather than inflammatory process. The disease was unilateral, progressive and refractory to repeated courses of topical and systemic antibiotic therapy. In addition, otoscopic examination revealed a discrete polypoid mass rather than diffuse canal edema and audiologic testing demonstrated conductive hearing loss attributable to mechanical obstruction. These findings, taken together, should prompt consideration of biopsy or surgical excision to exclude underlying neoplastic pathology in patients with chronic external auditory canal disease.

The differential diagnosis for polypoid lesions of the external auditory canal is broad and includes inflammatory polyps, cholesteatoma, benign ceruminous gland tumors and malignant neoplasms such as squamous cell carcinoma. While cholesteatoma is often suspected in cases of chronic otorrhea and conductive hearing loss, it is typically associated with middle ear disease and bony erosion. In contrast, benign ceruminous gland tumors such as cystic hidradenoma may present as isolated canal lesions without deeper extension, as observed in this patient.

Ceruminous gland tumors are rare and cystic hidradenoma represents an exceptionally uncommon benign subtype. These tumors lack distinctive clinical or radiographic features and may closely mimic inflammatory granulation tissue. As demonstrated in (Table 2), benign and neoplastic lesions may share clinical features, particularly when it comes to laterality and duration. Definitive diagnosis relies on histopathologic evaluation following excision.

Characteristic findings include a well circumscribed lesion with solid and cystic architecture composed of bland epithelial cells, often with clear cytoplasm and without cytologic atypia or invasive growth. These features distinguish cystic hidradenoma from malignant ceruminous neoplasms, which carry significantly different prognostic and therapeutic implications.

Imaging studies such as computed tomography or magnetic resonance imaging can aid in assessing lesion extent and excluding bony erosion or middle ear involvement when

malignancy is suspected. However, imaging is limited in its ability to distinguish among soft tissue lesions of the external auditory canal and should not delay tissue diagnosis in refractory cases^{2,9,18}. In this patient, the decision to proceed with surgical excision was driven by clinical features summarized in Table 1 rather than radiographic findings alone.

Table 2: Comparison of Diagnostic Criteria of External Ear Canal Lesions.

Feature	Inflammatory Etiology	Neoplastic Etiology	This Case
Laterality	Often bilateral	Typically, unilateral	Unilateral
Response to antibiotics	Improves	Minimal or transient	Transient
Lesion appearance	Diffuse edema	Discrete polypoid mass	Polypoid
Hearing loss	Variable	Conductive	Conductive
Duration	Acute or relapsing	Progressive	Chronic
Need for histology	Not required	Required	Required

Complete surgical excision is the treatment of choice for cystic hidradenoma of the external auditory canal and is considered curative when clear margins are achieved^{2,8,10}. In this case, a trans-canal approach allowed for complete resection with resolution of otorrhea and improvement in hearing. At six-month follow-up, there was no evidence of recurrence. Published outcomes in the limited literature similarly demonstrate excellent prognosis following complete excision, with recurrence being rare^{14,15}. Given the scarcity of cases and the absence of standardized surveillance guidelines, periodic clinical follow-up is reasonable^{19,20}.

Conclusion

Cystic hidradenoma of the external auditory canal is a rare benign ceruminous gland tumor that can closely mimic chronic infectious or inflammatory ear disease. This case underscores the importance of maintaining neoplastic etiologies in the differential diagnosis of refractory unilateral external auditory canal pathology. When standard medical therapy fails to resolve chronic otorrhea or polypoid canal lesions, biopsy or surgical excision is essential for accurate diagnosis. Complete surgical excision is both diagnostic and definitive, with excellent outcomes and low risk of recurrence. Increased awareness of this rare entity may help prevent delayed diagnosis and unnecessary prolonged medical treatment.

References

1. Dehner LP, Chen KT. Primary tumours of the external and middle ear: benign and malignant glandular neoplasms. *Arch Otolaryngol* 1980;106(5):252-258.
2. Nagarajan P. Ceruminous neoplasms of the ear: clinical, radiologic and histologic features. *Head Neck Pathol* 2018;12(3):350-361.
3. Lassaletta L, Patron M, Oloriz J, et al. Avoiding misdiagnosis in ceruminous gland tumours. *Auris Nasus Larynx* 2003;30(3):287-290.
4. Psillas G, Krommydas A, Karayannopoulou G, et al. Ceruminous adenoma of the external auditory canal. *Eur Arch Otorhinolaryngol* 2015;272(6):1499-1505.
5. Wetmore SJ. Lesions of the external auditory canal. *Otolaryngol Clin North Am* 1996;29(5):807-825.

6. Yuen HW, et al. External auditory canal lesions. *Singapore Med J* 2007;48(8):748-754.
7. Ramli SS, Abdullah A, Md Pauzi SH, et al. Ceruminous adenoma: a rare mass that impairs hearing. *Case Rep Otolaryngol* 2021;2021:8876049.
8. Drviš P, Ries M, Zurak K, et al. Hidradenoma of the external auditory canal. *Coll Antropol* 2012;36(2):159-161.
9. Mansour P, George MK. Tumours of the external auditory canal. *Otolaryngol Clin North Am* 2008;41(1):43-62.
10. Stelow EB, Bishop JA. Ceruminous gland tumours. *Head Neck Pathol* 2015;9(3):282-290.
11. Mills SE, Cooper PH, Fechner RE. Hidradenoma and hidradenocarcinoma of the skin. *Cancer* 1982;50(3):521-529.
12. Calonje E, et al. Adnexal tumours of the skin. *Am J Dermatopathol* 2009;31(5):417-438.
13. Shimon SV, Alenezi SM, Camela E, et al. Ectopic hidradenoma papilliferum of the external auditory canal. *J Laryngol Otol* 2024;138(4):287-291.
14. Djalilian HR, et al. Benign tumours of the external auditory canal. *Otol Neurotol* 2005;26(4):679-683.
15. Pichi B, et al. Ceruminous gland tumours: outcomes after surgical excision. *Acta Otorhinolaryngol Ital* 2019;39(2):92-99.
16. Srivalli M, Qaiyum HA, Moorthy PN, et al. Adenomatous neoplasia presenting as aural polyp. *J Clin Diagn Res* 2011;5(7):1461-1463.
17. Thompson LD. Ceruminous gland neoplasms of the ear. *Ear Nose Throat J* 2017;96(2):7-14.
18. Moody SA, Hirsch BE, Myers EN. Squamous cell carcinoma of the external auditory canal. *Am J Otol* 2000;21(4):582-588.
19. Yang Y, Liu H, Fang J, Li Y, Chen S. Ceruminous adenoma of the external auditory canal. *Front Oncol* 2023;13:1041282.
20. Wenig BM. Tumours of the ear. *AFIP Atlas of Tumour Pathology*. 4th Series 2011.