

## A Rare Case of Cervical Vagus Nerve Schwannoma in an Adult Patient: Diagnostic and Therapeutic Strategy

F El Mourabit\*, S Moujrid, A Rhnia, M Loudghiri, W Bijou, Y Oukessou, S Rouadi, R Abada, M Roubal, M Mahtar

Department of Otolaryngology Head and Neck Surgery, University hospital Ibn Rochd, Casablanca, Morocco

**Citation:** El Mourabit F, S Moujrid, A Rhnia, et al. A Rare Case of Cervical Vagus Nerve Schwannoma in an Adult Patient: Diagnostic and Therapeutic Strategy. *Medi Clin Case Rep J* 2024;2(4):488-491. DOI: doi.org/10.51219/MCCRJ/Fadoua-El-Mourabit/132

**Received:** 31 July, 2024; **Accepted:** 01 October, 2024; **Published:** 04 October, 2024

\***Corresponding author:** Fadoua El Mourabit, Department of Otolaryngology Head and Neck Surgery, University hospital Ibn Rochd, Casablanca, Morocco, Email: fadouaelmourabit1993@gmail.com

**Copyright:** © 2024 Mourabit FEL, et al., This is an open-access article distributed under the terms of the Creative Commons Attribution License, which permits unrestricted use, distribution, and reproduction in any medium, provided the original author and source are credited.

### ABSTRACT

Schwannomas originating from the Schwann cells are a rather uncommon benign tumor. Schwannomas often don't cause any symptoms, but larger tumors may cause vague symptoms because they squeeze nearby anatomical tissues. The pathognomonic symptoms of vagus nerve schwannomas are isolated neck masses, hoarseness of voice and paroxysmal coughing that occurs upon palpation. Imaging tests may be quite important in making a difficult preoperative diagnosis. The preferred course of treatment is surgery that removes the tumor entirely. Nerve damage during surgical resection is associated with significant morbidity. We report a case of vagus nerve schwannoma in a male adult patient in this study.

**Keywords:** Schwannoma; Vagal schwannoma; Vagus nerve; Cervical mass; Magnetic Resonance imaging

### Introduction

Schwann cells give rise to the benign tumor known as schwannoma, which grows slowly<sup>1-6</sup>. Another name for it is a neurilemmoma<sup>1,7</sup>. In 1908, Prague doctor Josay Verocay was the first to characterize schwannoma as a pathological disease<sup>1</sup>. Less than 5% of soft tissue sarcomas are malignant schwannomas; the remainder are benign<sup>8,9</sup>. Schwannomas equally impact the sexes. Although it can affect people of any age, the majority of instances occur in those between the ages of three and five. The likelihood of a malignant change in them is extremely low<sup>1,4-7,10,11</sup>. Of the instances, extracranial schwannomas make up between 1/4 and 1/3 of the total. The primary site of origin in the neck region is the vagus nerve, which is followed by the cervical sympathetic chain. When combined, they make up around 25% of all extracranial schwannomas in the head and neck<sup>12,13</sup>. There are two types of cervical schwannomas: medial and lateral. The last four cranial nerves or the cervical sympathetic chain, give rise to the medial groups. The groups that emerge from

the cervical or brachial plexus trunk are known as the lateral groups<sup>1,8</sup>. A rare tumor called extracranial cervical vagal nerve schwannoma (VNS) usually manifests itself between the ages of three and five. As of 2016, there are only 133 cases that have been reported in the literature<sup>3,11</sup>. Furthermore, the literature only has 50 cases of cervical sympathetic schwannoma<sup>8</sup>.

A rare tumor called extracranial cervical vagal nerve schwannoma (VNS) usually manifests itself between the ages of three and five. As of 2016, there are only 133 cases that have been reported in the literature<sup>3,11</sup>. Furthermore, the literature only has 50 cases of cervical sympathetic schwannoma.<sup>8</sup>The main symptom of patients with VNS in the neck is hoarseness because of vocal cord paralysis.

When the mass is palpated, patients may also have an involuntary cough, which clearly suggests the origin of the vagal nerve<sup>3,4,6,7,10,11,14</sup>. Dysphonia and dysphagia are other possible symptoms, especially if the tumor is large<sup>11</sup>.

Preoperative consideration of schwannomas is highly challenging due to their rarity and the absence of a neurologic dysfunction as a presenting symptom. When it comes to neck tumors, a number of differential diagnoses might be considered. These include lipomas, teratomas, thyroid cysts or nodules, inflammatory cervical lymphadenopathy, submandibular salivary gland tumors, neurofibromas, and metastatic cervical lymphadenopathy<sup>1,3,6,7,10,11,13,14</sup>. Complete surgical resection is the cornerstone of treatment, but due of its close proximity to the carotid artery and the vagus nerve, from which it originates, it may be technically difficult<sup>3,4</sup>. The tumor's location, size, and relationship to surrounding vessels all influence the strategy. The main side effect after VNS excision is hoarseness of voice<sup>4</sup>.

## Case Report

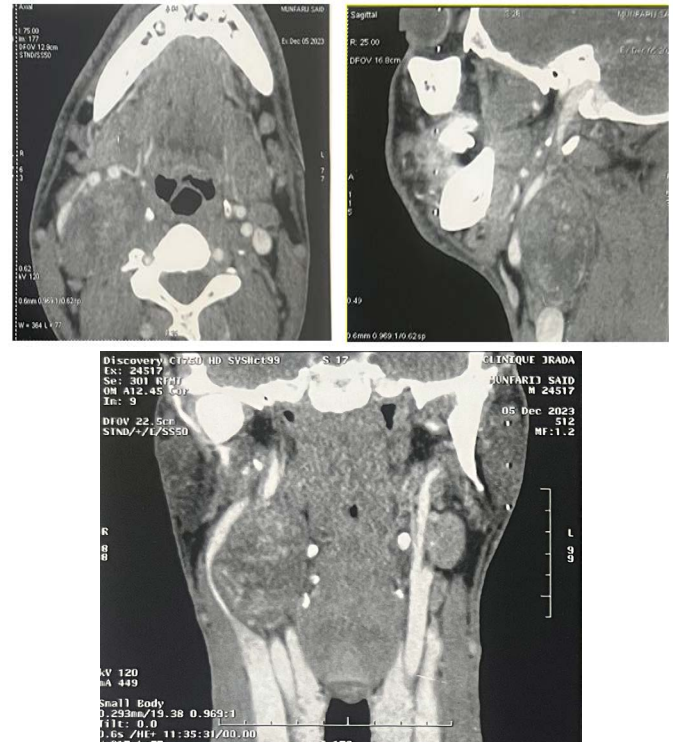
A 26-year-old male patient was referred to the outpatient clinic of the Oral and Maxillofacial Surgery Department with a history of a mass in the right lateral neck area. patients with no specific pathological antecedents. The history of her illness goes back to 1 year the history of his malaria goes back 1 year with the appearance of a right latero cervical mass progressively increasing in volume with no inflammatory signs opposite, no associated compressive signs and no fistulization to the skin. However, the patient had begun to experience some nonspecific symptoms in the previous year. The main complaints were mild hoarseness of voice, episodes of bradycardia. His physical examination revealed, a non-tender well-limited soft, painless right latero-cervical mass, mobile in relation to the 2 planes involving sectors 2 and 3, with no inflammatory signs opposite the mass. Notably, the palpation of the neck induced paroxysmal cough. No cervical lymph nodes were palpated. All the cranial nerve examinations were normal. At the nasofibroscopy: no backflow or visible mass the 2 vocal cords are mobile.

On the cervical CT scan, a voluminous mass well limited to the right side of the cervix with carotid and jugular vascular contact, the site of some calcification without contrast in arterial washout or typical intercarotid topography, suggesting a glomus origin. (Figure 1).

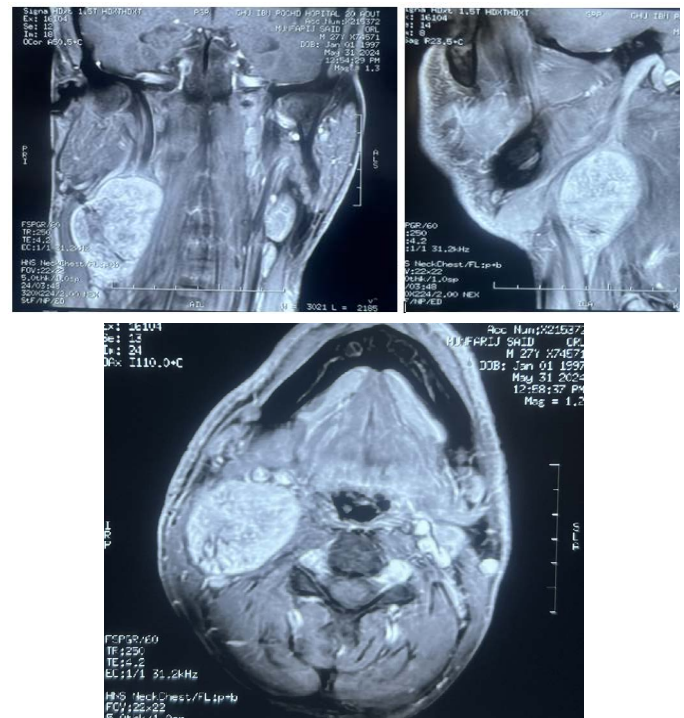
Magnetic resonance imaging (MRI) of the neck confirmed a 39x38x60 mm properly limited mass with high signal intensity on T1-weighted MRI and a heterogeneous, low signal intensity on T2 weighted MRI (Figure 1). After intravenous administration of gadolinium-based contrast material, the lesion showed irregular peripheral enhancement. Carotid artery angiography was performed because of the close relationship between the mass and the carotid artery. The angiography showed a normal filling in the right common, internal, and external carotid arteries and their branches. (Figure 2).

Under general anesthesia, an oblique cervical incision was made starting from the right mastoid apex. A yellowish mass lesion was observed that was 5x4cm in diameter, originating from the vagus nerve and medially adjacent to the common carotid artery. It was extending laterally to the internal jugular vein and sternocleidomastoid (SCM) muscle, and superiorly to the skull base (Figure 2). The mass was carefully dissected from the vagus nerve and other adjacent structures, with care taken to protect the vagal nerve's integrity. The specimen was sent for frozen section and a schwannoma originating from the vagus nerve was confirmed. No extra surgical intervention was considered and the operation was completed. Postoperative

follow up of the patient was uneventful and he was discharged on the 7th postoperative day.



**Figure 1:** CT imaging of a vagal schwannoma (red arrow) on the right cervical side: (A) sagittal (B) axial and coronal (C) view.



**Figure 2:** Coronal (A) sagittal (B) and axial(C) view. Gray arrow: well-circumscribed, h mass with dimensions of 39x38x60 mm in the right lateral cervical region directly under the right sternocleidomastoid muscle, separating the internal jugular vein and the carotid artery. Yellow arrow: compressed internal jugular vein. Black arrow: carotid artery.

## Discussion

Schwannomas in the head and neck are slow-growing, benign tumors. But it's crucial to remember that malignant transformation occurs with an incidence rate of 8-13.9%, which

is something to keep in mind when managing schwannoma<sup>2</sup>. They most often occur as a single mass, and they are typically asymptomatic. In the later stages, other nonspecific symptoms such as dysphagia, nasal obstruction, and dyspnea in the supine position arise because the surrounding anatomical structures are compressed by the larger mass<sup>2</sup>. Upon cervical mass palpation, patients with vagus nerve schwannomas may occasionally show with hoarseness of voice and a particular pathognomonic symptom of paroxysmal cough<sup>1,2</sup>. Inflammatory cervical lymphadenitis, metastatic lymphadenopathy, salivary gland neoplasms, paraganglioma, lymphoma, branchial cleft cyst, carotid body tumors, neurofibroma, and carotid aneurysm should all be considered in the differential diagnosis of such neck form<sup>3</sup>.

On the other hand, preoperative imaging tests and fine needle aspiration cytology (FNAC) may be useful in supporting the diagnosis. Furthermore, because imaging tests provide information about the lesion and the surrounding anatomy, they are crucial to surgical planning<sup>1</sup>. Since MRI offers a more thorough depiction of the soft tissues, it is seen as being preferable in this situation versus CT scans<sup>1,2</sup>. Schwannomas with high attenuation relative to the surrounding muscle with low to moderate heterogeneous contrast enhancement are described by contrast-enhanced computed tomography scans. Internal cystic alterations resulting from bleeding, necrosis, or mucinous degeneration are occasionally seen. T2-weighted MR pictures reflect a heterogeneously hyperintense signal, but T1-weighted MR images display the isointense signal of the schwannoma in relation to the surrounding muscle.

Imaging can show how the mass relates to nearby structures and provide some information about the mass composition, which is helpful in differentiating between the items in the differential list. The contents of the carotid sheath can be displaced to distinguish between vagal and cervical sympathetic chain schwannomas. Vagal schwannomas tend to divide the internal jugular vein and carotid artery, whereas the latter shift both laterally since they are not inside the carotid sheath. Since cervical lymph nodes are lateral to the carotid sheath, lymph node involvement might be taken into consideration when both the carotid and jugular veins are moved medially. At the carotid bifurcation level, carotid body tumors divide the carotid arteries into the internal and exterior segments<sup>7</sup>. Schwannomas appear round or elliptical on ultrasound imaging, with distinct borders and internal echo reflection. Ultrasound can show the link between the nerves if the diameter of the originating nerve is large enough<sup>1</sup>.

Schwannomas typically appear inhomogeneous on CT, with a well-defined mass linked to peripheral enhancement and interior cysts<sup>8</sup>. The most precise and sensitive preoperative method is magnetic resonance imaging (MRI), which enables a more precise determination of the nerve of origin. Specific indications (split fat, fascicular, target) and signal patterns (low signal intensity on T1-weighted images, high signal intensity on T2-weighted images) on MRI are indicative of schwannomas<sup>9</sup>. On improved T1 imaging, certain authors have shown that a schwannoma is a lesion with a particular peripheral hyperintense rim and center low intensity<sup>10</sup>. Furthermore, MRI rather than CT may be able to clarify the connection between the schwannoma and its originating nerve.

Surgical indications for the treatment of extracranial head and neck schwannomas should carefully consider the advantages

of the procedure against the possibility of nerve palsy following excision. Several treatment strategies, including radical tumor excision, intracapsular enucleation, and waiting and seeing, have been suggested for the management of schwannomas<sup>11</sup>. Generally, the tumor's size, location, and relationship to nearby vessels determine which technique is best.

Although the surgical technique is the preferred course of action, the observational strategy is also warranted due to the lesion's noninvasive nature and sluggish progression. Intracapsular enucleation, debulking, and radical excision with nerve grafting are the primary surgical alternatives<sup>12</sup>. Radical excision is removing the tumor entirely while sacrificing the perineum's nerves that are attached to it. Nerve transplantation is therefore scheduled. A more conservative procedure called intracapsular resection involves removing just the tumor's core while maintaining the tumor capsule connected to the perineum. Recurrence risk is elevated with tumor debulking. Nerve integrity may not always be preserved even with intracapsular dissection, therefore prior to surgery, patients should be well informed about It may be difficult to maintain nerve integrity even with intracapsular dissection, thus patients should be fully told about the possibility of neurologic impairments prior to surgery. Surgery's primary objective should always be to remove the tumor with the least amount of neurologic damage. The nerve of origin is probably going to be impacted by the procedure used. According to reports, 100% and 67% of patients experience nerve palsy after intracapsular dissection and full excision, respectively<sup>13</sup>.

Intracapsular enucleation is the preferred method of tumor removal because the complications are usually temporary and treatment is not necessary in most cases; in fact, some authors report a preservation of neural function of more than 30% when compared to radical tumor resection with a primary anastomosis<sup>14</sup>. It's interesting to note that a number of studies have demonstrated that surgeons can keep good vocal function after surgery by protecting nerves as much as possible by knowing the anatomical features of the recurrent laryngeal and nonlaryngeal reflexes and the eccentric growth pattern of the tumor<sup>15,16</sup>. Additionally, some writers suggest using an electromyography (EMG) system during tumor removal as a way to assist prevent motor nerve paralysis in the treatment of extracranial schwannomas of the head and neck. This could help preserve function. A comparable approach has been used in clinical practice for parotid gland and thyroid surgery<sup>17</sup>.

According to numerous reports in the literature, primary repair or a nerve transplant should be carried out using a microsurgical method, with or without medialization of the vocal cord, if the nerve cannot be saved during surgery<sup>21</sup>. Lastly, a wait-and-see strategy was proposed by some writers<sup>18</sup>, delaying surgery only in the event that the symptoms deteriorate and neurological weakening turns out to be clinically significant. After a vagal nerve schwannoma is removed, common postoperative issues arise because the tumor originated directly from the nerve fibers. These consist of vocal cord palsy, nerve damage, and voice hoarseness. As a result, post-operative care and preoperative evaluation of speech and swallowing are crucial to these patients' voice and swallowing rehabilitation. In particular, the majority of patients report having hoarseness. These consist of vocal cord palsy, nerve damage, and voice hoarseness. As a result, post-operative care and preoperative evaluation of speech and



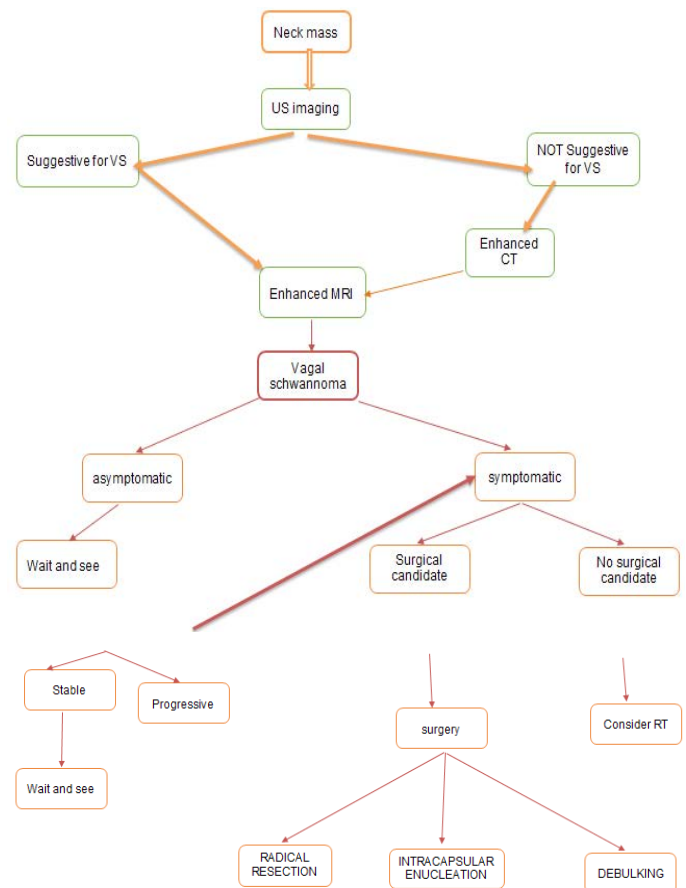
swallowing are crucial to these patients' voice and swallowing rehabilitation. To be more precise, after schwannoma removal, hoarseness is noted by the majority of patients, but after tumor resection, vocal cord paralysis affects 85% of patients. Pharyngolaryngeal anesthesia, aspiration, and cranial nerve palsies IX, XI, and XII are additional frequent side effects after schwannoma excision that may be temporary or permanent<sup>19</sup>. Lastly, Horner's syndrome and changes in heart rate are two further rare problems that have been reported<sup>20</sup>.

The vagus nerve lowers heart rate, a fact that has been extensively reported in the literature<sup>22</sup>. Patients who are not candidates for surgery might benefit from radiation therapy if they are symptomatic or from an observational strategy (i.e., "wait and see"), albeit the research does not provide sufficient evidence to support either course of action. In contrast to the auditory nerve, which is primarily treated with radiation, there is really less data regarding the effectiveness of radiation for schwannomas of the head and neck<sup>23</sup>. However, there is growing evidence supporting the use of radiation therapy for non-surgical candidates with schwannomas of other cranial nerves (III, IV, V, and VI), with a local control rate ranging from 90% to 100%<sup>24,25</sup>. Regarding the radiobiological behavior of vagal schwannomas specifically, several writers have highlighted that this entity's inherent radioresistance serves as one of the primary barriers to the effectiveness of radiation therapy<sup>29</sup>. Because of this, the standard schedule choice described in the literature for comparable clinical situations is usually hypofractionated and requires the use of stereotactic radiotherapy<sup>26</sup>.

However, it is important to consider the possibility of acute adverse events when contemplating radiotherapy as an alternate therapeutic option for surgical candidates. These adverse events typically resolve on their own and can be made better by giving small doses of steroids. Large-volume and dumbbell-shaped tumors are important predictors of the incidence of these acute adverse effects<sup>27</sup>. Regarding the potential use of a wait-and-see strategy, it is crucial to suggest it only to patients who agree to routinely visit the doctor and undergo imaging exams as directed by the doctor; in fact, protocol may be changed to active treatment in cases of radiologic growth, pain, or new cranial nerve dysfunction<sup>28</sup>.

It is difficult to control anesthesia during the excision of a vagal nerve schwannoma. There have been reports of severe bradycardia resulting in hypotension and anomalies in the ECG<sup>5</sup>. Mukherjee et al.'s patient went into cardiac arrest while having a sizable vagal schwannoma removed<sup>6</sup>. Direct vagal stimulation was assumed to be the most likely cause of cardiac arrest. In addition, our patient had two episodes of bradycardia with hypotension, which made injecting atropine necessary because the mass release performed by the surgeon had not been very helpful. When inducing anesthesia, every effort was made to avoid employing anesthetics that could cause bradycardia. With the bulk removed, there was no more bradycardia episode. To stop a recurrence, the tumor capsule must be completely removed<sup>4</sup>.

Postoperative reports indicate that hoarseness occurs in nearly all instances, while 85% of cases result in spinal cord paralysis<sup>4</sup>. It is crucial to evaluate the voice cords' range of motion prior to surgery. Therefore, as part of the preoperative evaluation, the anesthetist must also advise the patient about potential postoperative neurological problems.



## Conclusion

Vagus nerve schwannomas are rarely occurring neck masses. The identification and treatment of vagal schwannomas are undoubtedly difficult in the clinical setting. In actuality, symptoms are typically non-specific, which could cause delays in diagnosis. Imaging is a very helpful modality for diagnosis and surgical planning. Furthermore, it should be carefully addressed because post-operative sequelae, such as vagal nerve injury, still represent important issues, even though complete surgical resection is the standard therapeutic method. We have offered a vagal schwannomas care algorithm based on a combination of scientific data from the literature and our clinical expertise.

## References

- Behuria S, Rout TK, Pattanayak S. Diagnosis and management of schwannomas originating from the cervical vagus nerve. *Ann R Coll Surg Engl* 2015;97:92-97.
- Kanatas A, Mücke T, Houghton D, Mitchell DA. Schwannomas of the head and neck. *Oncol Rev* 2009;3:107-111.
- Cavallaro G, Pattaro G, Iorio O, Avallone M, Silecchia G. A literature review on surgery for cervical vagal schwannomas. *World J Surg Oncol* 2015;13:130.
- Chiofalo MG, Longo F, Marone U, Franco R, Petrillo A, Pezzullo L. Cervical vagal schwannoma. A case report. *Acta Otorhinolaryngol Ital* 2009;29:33-35.
- Wood BM, McNeil WT. Schwannoma of the vagus nerve. *Anaesthesia* 1986;41:1130-1132.
- Mukherjee DK. Neurilemmoma of the vagus nerve, A case report. *J Laryngol Otol* 1979;93(2):187-192.
- Sandler ML, Sims JR, Sinclair C, et al. Vagal schwannomas of the head and neck: a comprehensive review and a novel approach to preserving vocal cord innervation and function. *Head Neck* 2019;41(7):2450-2466.

8. Kim SH, Kim NH, Kim KR, Lee JH, Choi HS. Schwannoma in head and neck. Preoperative imaging study and intracapsular enucleation for functional nerve preservation. *Yonsei Med J* 2010;51(6):938-942.
9. Dosemane D, Kabekkodu S, Jaipuria B, Sreedharan S, Shenoy V. Extracranial non-vestibular head and neck schwannomas. A case series with the review of literature. *Braz J Otorhinolaryngol* 2022;88:9-17.
10. Crist J, Hodge JR, Frick M, Leung FP, Hsu E, Gi MT, Venkatesh SK. Magnetic Resonance Imaging Appearance of Schwannomas from Head to Toe. A Pictorial Review. *J Clin Imaging Sci* 2017;7:38.
11. Gibber MJ, Zevallos JP, Urken ML. Enucleation of vagal nerve schwannoma using intraoperative nerve monitoring. *Laryngoscope* 2012;122(4):790-792.
12. Akheel M, Mohd Athar I, Ashmi W. Schwannomas of the head and neck region: A report of two cases with a narrative review of the literature. *Cancer Res Stat Treat* 2020;3(3):517-525.
13. Wang B, Yuan J, Chen X, Xu H, Zhou Y, Dong P. Extracranial non-vestibular head and neck schwannomas. *Saudi Med J* 2015;36(11):1363-1366.
14. Valentino J, Boggess MA, Ellis JL, Hester TO, Jones RO. Expected neurologic outcomes for surgical treatment of cervical neurilemmomas. *Laryngoscope* 1998;108(7):1009-1013.
15. Lin J, Martel W. Cross-sectional imaging of peripheral nerve sheath tumors: Characteristic signs on CT, MR imaging, and sonography. *Am J Roentgenol* 2001;176(1):75-82.
16. Xu T, Liu Y, Li S, Zheng L. Pre-operative embolization and excision of vagal schwannoma with rich vascular supply: A case report and literature review. *Medicine* 2022;101(4):28760.
17. Ijichi K, Kawakita D, Maseki S, Beppu S, Takano G, Murakami S. Functional Nerve Preservation in Extracranial Head and Neck Schwannoma Surgery. *JAMA Otolaryngol Head Neck Surg* 2016;142(5):479-483.
18. Gilmer-Hill HS, Kline DG. Neurogenic tumors of the cervical vagus nerve: Report of four cases and review of the literature. *Neurosurgery* 2000;46(6):1498-1503.
19. Khafif A, Segev Y, Kaplan DM, Gil Z, Fliss DM. Surgical management of parapharyngeal space tumors: A 10-year review. *Otolaryngol Head Neck Surg* 2005;132(3):401-406.
20. Kumar KP, Alam MS. "Collateral Damage": Horner's Syndrome Following Excision of a Cervical Vagal schwannoma. *Int. J. Appl. Basic Med. Res* 2018;8:190-192.
21. Pankratjevaite L, Dreyer NS, Dauksa A, Sarauskas V. Challenging diagnosis of cervical vagal nerve schwannoma. *J Surg Case Rep* 2022;2022(4).
22. Allen E, Pongpaopattanakul P, Chauhan RA, Brack KE, Ng GA. The Effects of Vagus Nerve Stimulation on Ventricular Electrophysiology and Nitric Oxide Release in the Rabbit Heart. *Front Physiol* 2022;13:867705.
23. Yafit D, Horowitz G, Vital I, Locketz G, Fliss DM. An algorithm for treating extracranial head and neck schwannomas. *Eur Arch Otorhinolaryngol* 2015;272:2035-2038.
24. Fionda B, Rembielak A. Is There Still a Role for Radiation Therapy in the Management of Benign Conditions? *Clin Oncol* 2023;35(11):698-700.
25. Kim IY, Kondziolka D, Niranjan A, Flickinger JC, Lunsford LD. Gamma Knife surgery for schwannomas originating from cranial nerves III, IV, and VI. *J Neurosurg* 2008;109:149-153.
26. Li Y, Lou J, Qiu S, Guo Y, Pan M. Hypofractionated stereotactic radiotherapy for dumbbell-shaped hypoglossal schwannomas: Two cases of long-term follow-up and a review of the literature. *Mol Clin Oncol* 2016;5(2):371-374.
27. Kim YG, Park CK, Jung NY, Jung HH, Chang JH, Chang JW, Chang WS. Early-onset adverse events after stereotactic radiosurgery for jugular foramen schwannoma: A mid-term follow-up single-center review of 46 cases. *Radiat Oncol* 2022;17(1):89.
28. Merzouqi B, El Bouhmadi K, Oukesou Y, et al. Head and neck paragangliomas: Ten years of experience in a third health center. A cohort study. *Ann Med Surg* 2021;66:102412.
29. Lahoti BK, Kaushal M, Garge S, Aggarwal G. Extra vestibular schwannoma: A two year experience. *Ind J Otolaryngol Head Neck Surg* 2011;63(4):305-309.